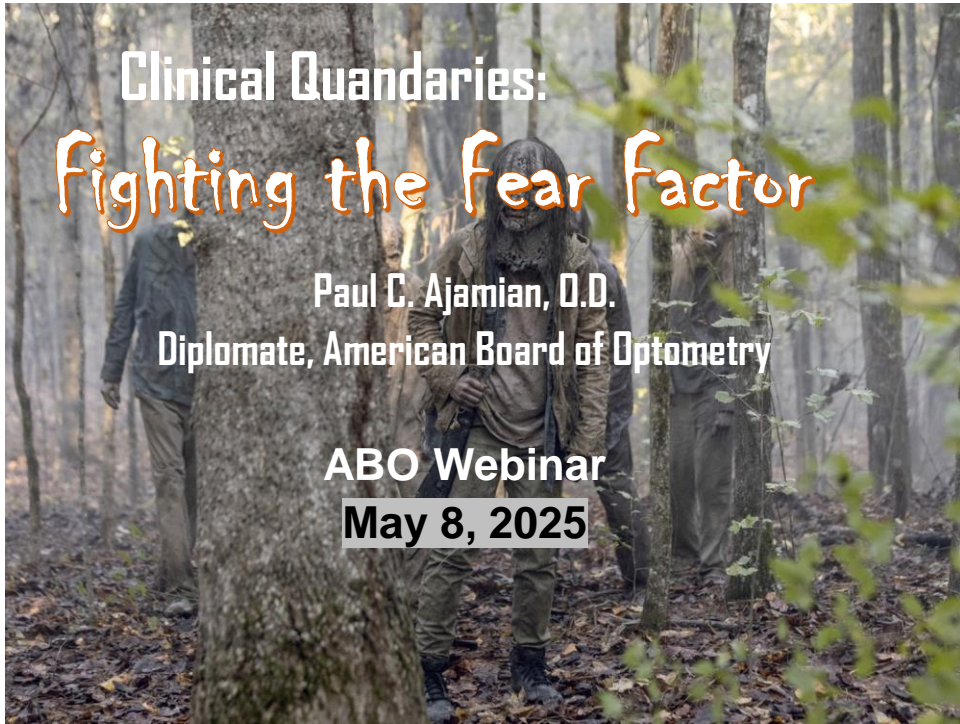

1

## Disclosures

- NO INDUSTRY DISCLOSURES TO REPORT

2

## EIGHT GREAT ways of fighting the Fear Factor (and keeping the lawyers away):

1. Be a good observer
2. Don't be afraid of stranger things
3. Calmly assess one finding at a time
4. Detective at work
5. Pick and Poke
6. Watery Eyes
7. Double Trouble
8. Final Factor: Stay out of Hot Water

3

Balancing Act: Don't over-refer but know your limitations

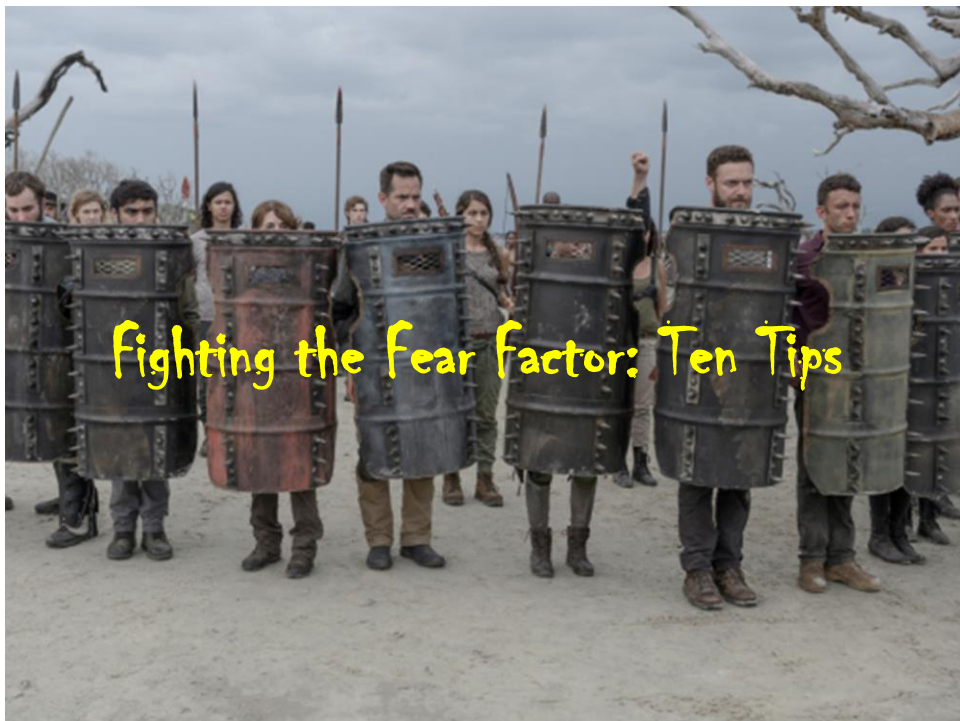


4

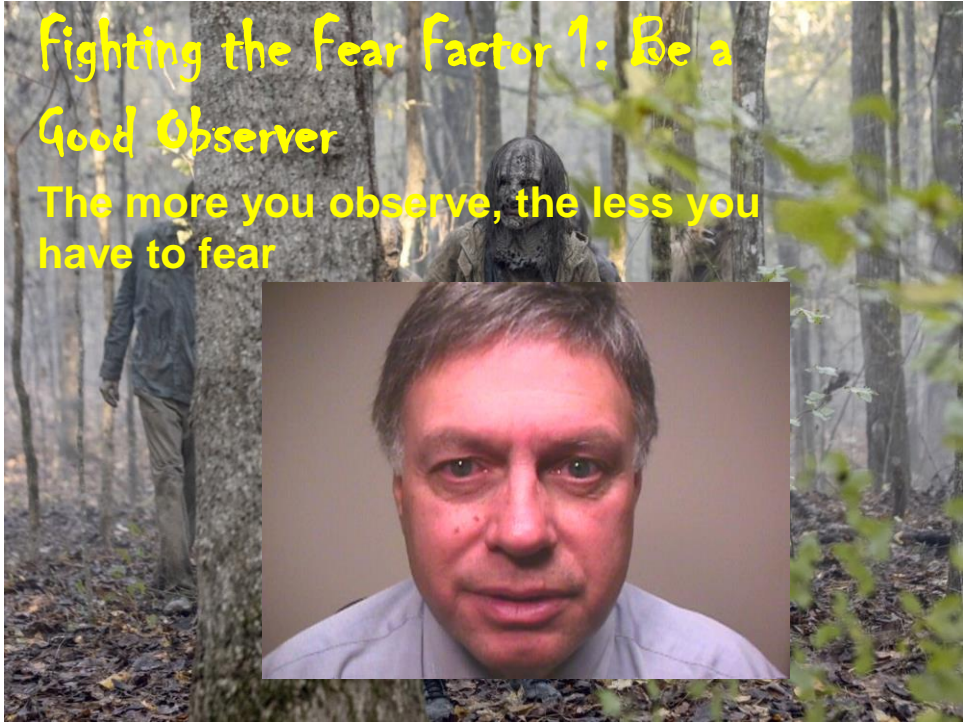## Basic Things:

- Send to the person you think is best (v. list)
- Work with great doctors that make you look good
- Make appointments for patients including labs and scans....if the test needs to be ordered then make sure it gets done ASAP

5



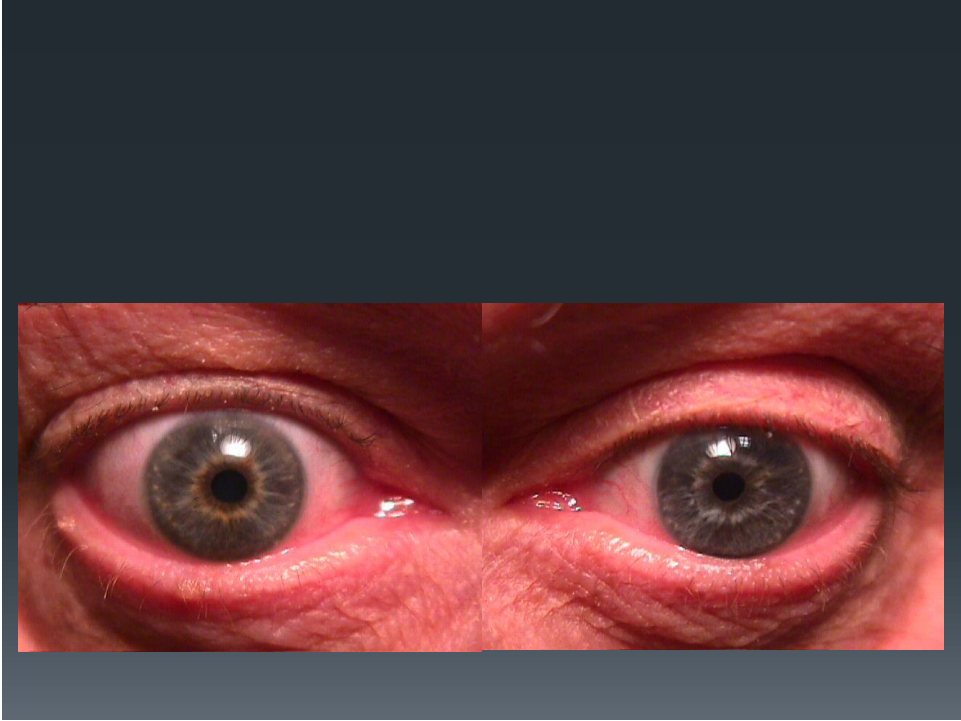
6



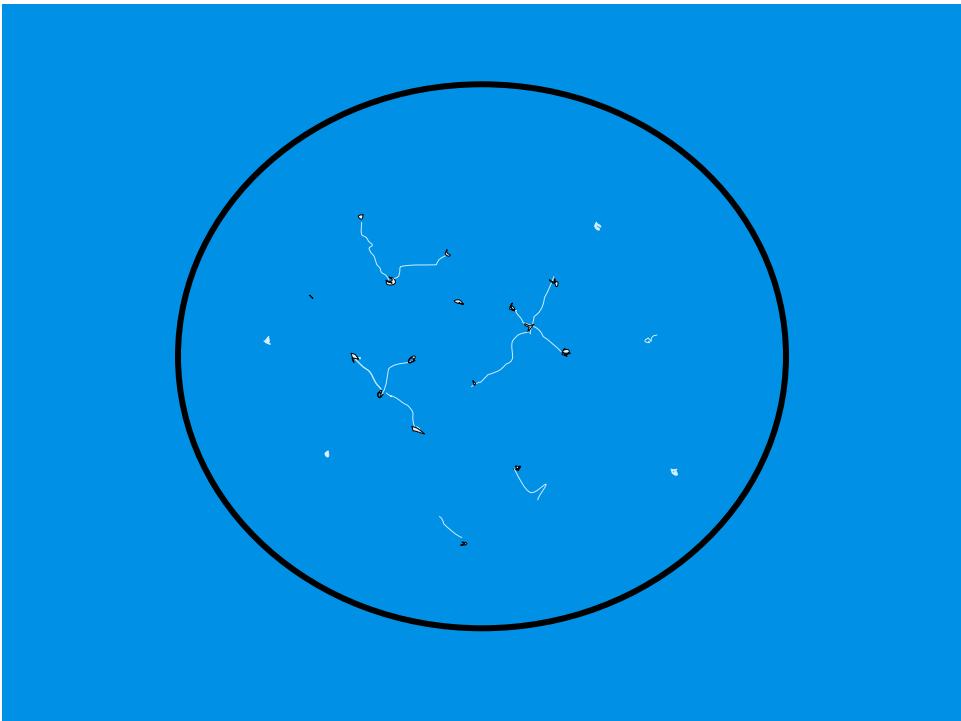
7



8



9



10

# Poll Question 1

11

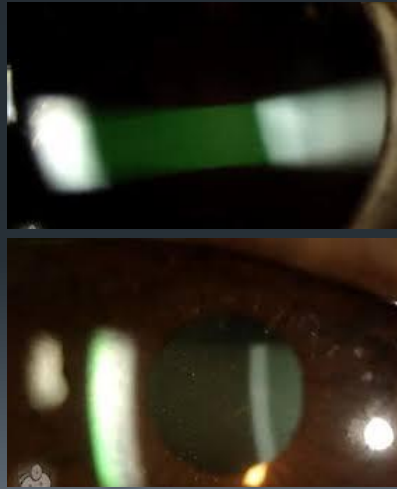## Fuch's Heterochromic Iridocyclitis

- No lab test will help you
- Definitive dx often delayed due to missing the subtle heterochromia, iris atrophy and stellate KP
- Manage the inflammation as best you can, but mostly manage the glaucoma and cataracts that can develop
- More on uveits later.....

12

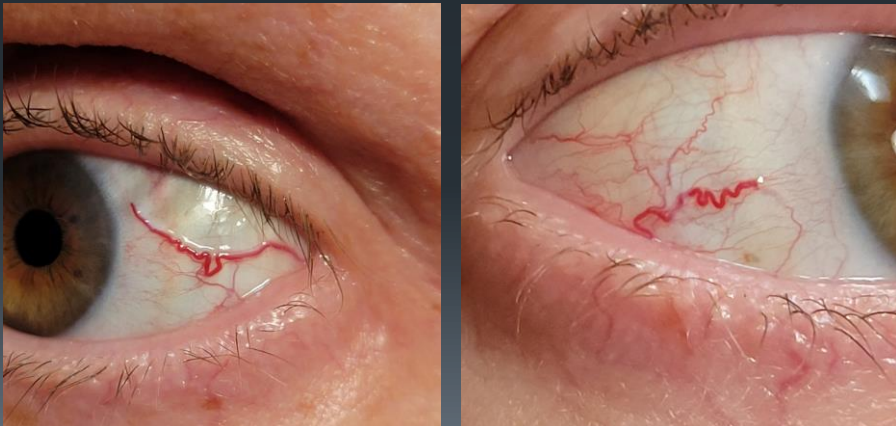## The more you observe, the less you have to fear

- Don't miss cell and flare: grade each separately
- Record/measure pupils, lid apertures, proptosis, lesions, corneal opacities, presence or absence of rubeosis



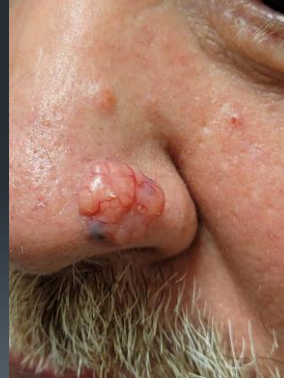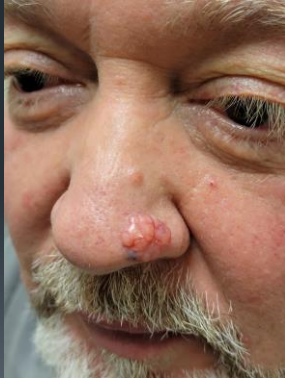13

## Don't just click the "external normal" or "slit lamp normal" button and call it a day



14

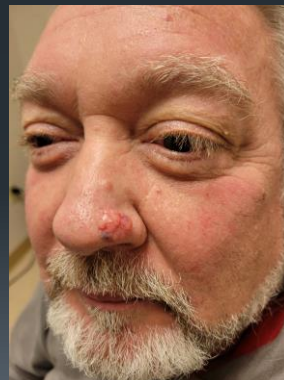## Be a Good Observer Save a Life!



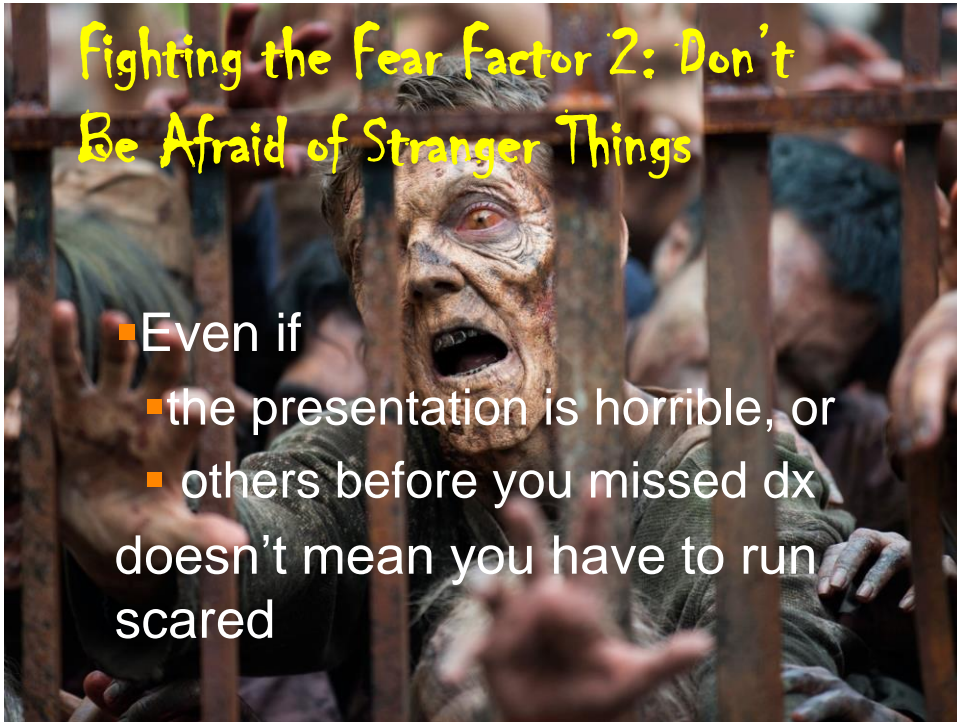
15

## He sure wasn't !

- "Its been there for over a year"
- When he finally got it checked at my insistence and using his wife as the enforcer, they also found squamous cell on his arm and melanoma on his back






16



17

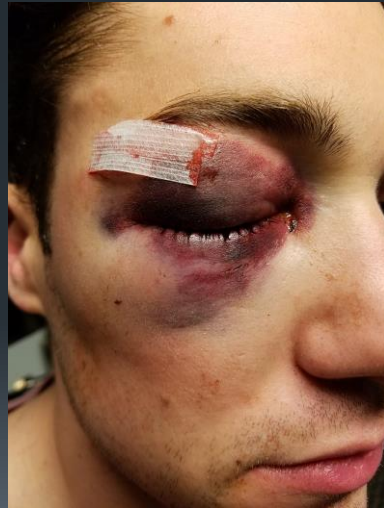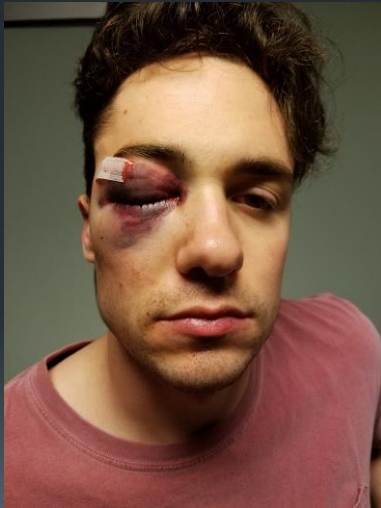**Trauma drama**

- ❖ 72 yo neighbor
- ❖ Sees OD who won't examine her, sends her right to the ED
- ❖ She calls me first

18

## 25 yo Bar Fight Participant



19

### Step by step:

- OPEN THE EYE, and get a meaningful VA
- MOTILITY SHOWS SUP GAZE RESTRICTION
- KNOWING IT'S A BLOW OUT FRACTURE, YOU CAN MORE INTELLIGENTLY TALK TO THE ORBITAL SPECIALIST ABOUT A PLAN:
  - MRI, ORAL STEROIDS AND ANTIHISTAMINES, AND TIMING OF THE REFERRAL

20

## Even if the presentation is horrible, or others before you missed dx doesn't mean you have to run scared

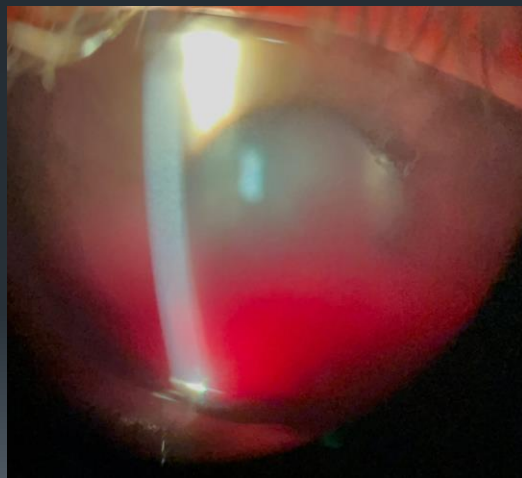
- HIGH IOPS DON'T MEAN "OUT THE DOOR"
  - HAVE A "FIRST AID KIT" OF GLAUCOMA SAMPLES
- PAIN DOESN'T MEAN ITS SERIOUS
- KIDS ARE PEOPLE TOO!



21

## 7 yo Granddaughter of Ref Doc

- Saturday Morning 7/22/23 hit in eye with three fishing weights by brother
- He is in south GA , his grand is in North GA.....can you see her?
- 30% Hyphema



22

## Findings

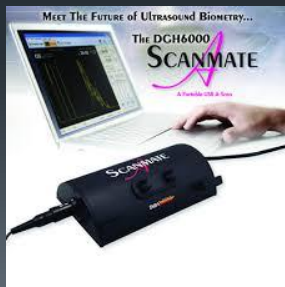
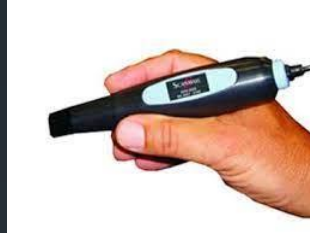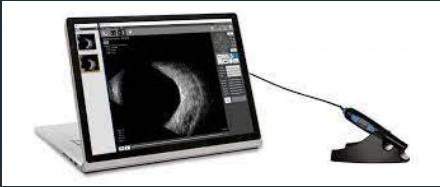- VA 20/30
- IOP 29
- Fundus view obscured but B Scan normal

23

## Poll Question 2

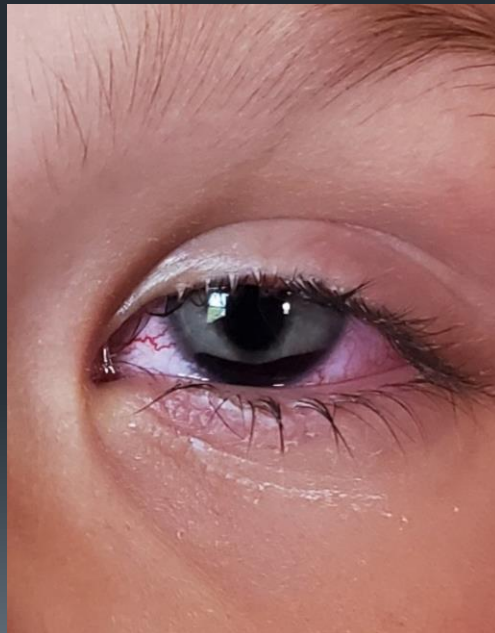24

# ? Add A/B Scan to your office



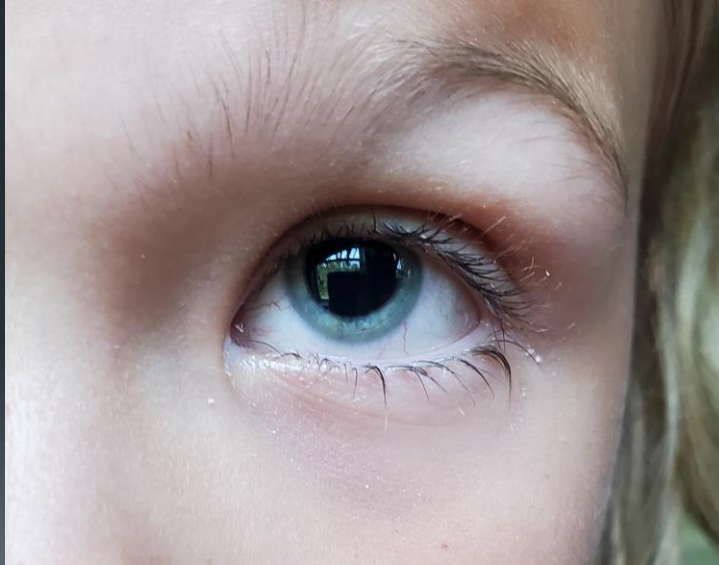25

# Next Day Sunday: 28 hours later



26

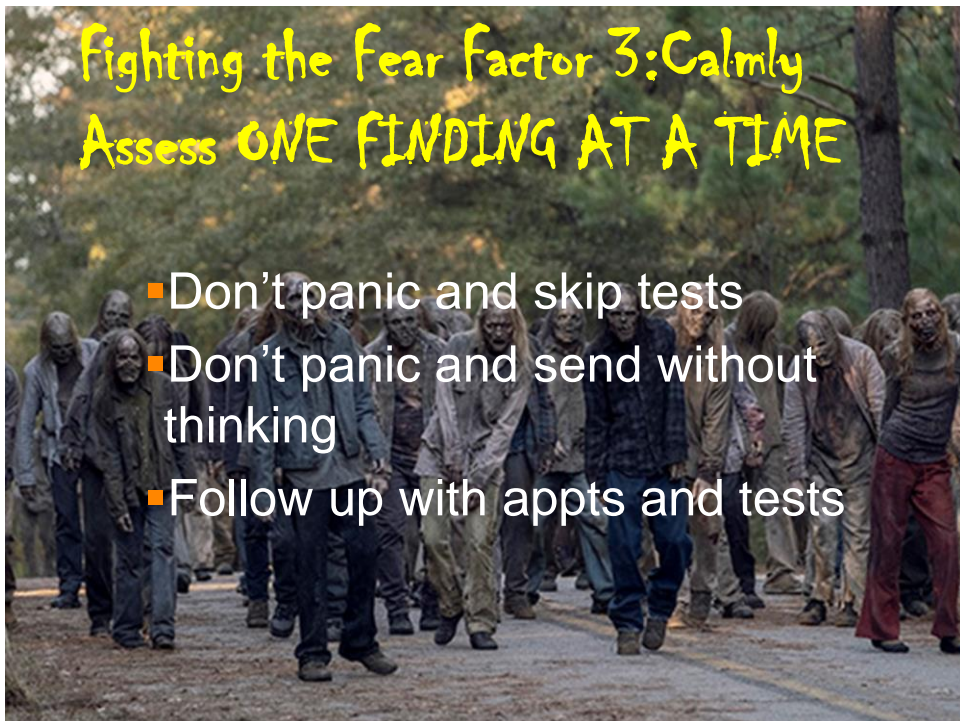
5 days after injury



27

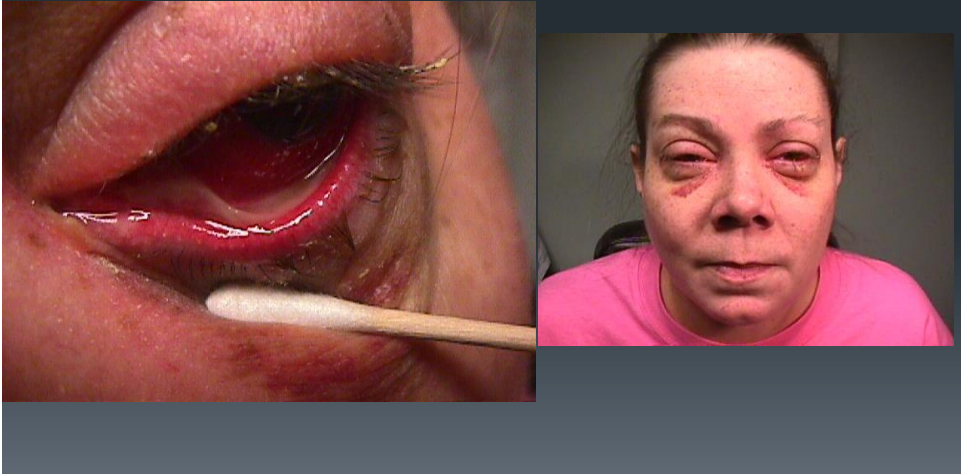
Fighting the Fear Factor 3: Calmly  
Assess ONE FINDING AT A TIME

- Don't panic and skip tests
- Don't panic and send without thinking
- Follow up with appts and tests



28

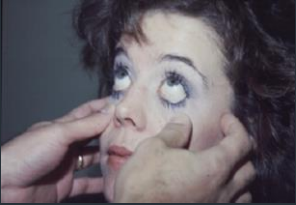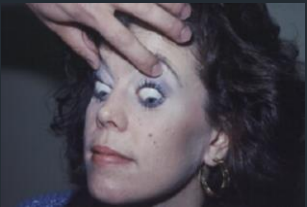# Who hit you?



29

## Before you panic and refer:

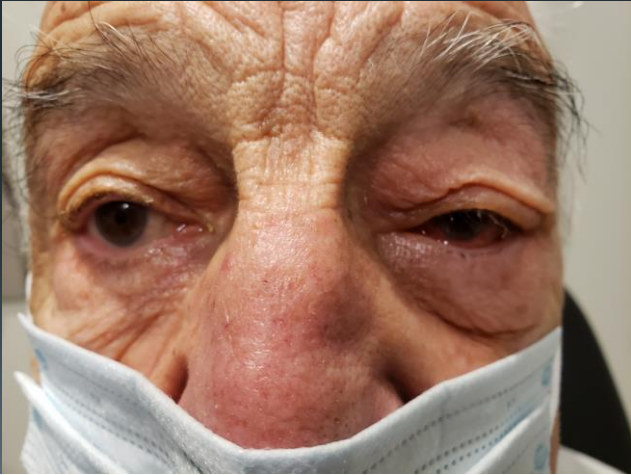- All red eyes get three extra tests besides a thorough history:
  - Get the big picture by having patient look up down left and right
  - Check for preauricular nodes
  - Evert lids



30


# 82 WM Neighbor and Friend "Paul I have Pink Eye"

- Sinus infection on a Thursday
- Wakes up with red swollen eye Friday



31

He was wondering if this drop would help



32

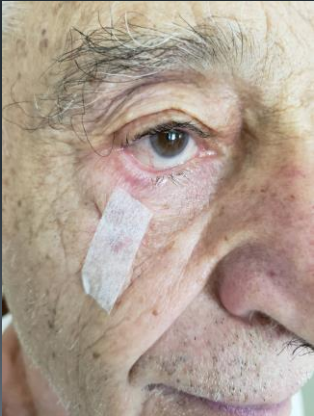# Flashback to 2019 when he presented with irritation RE



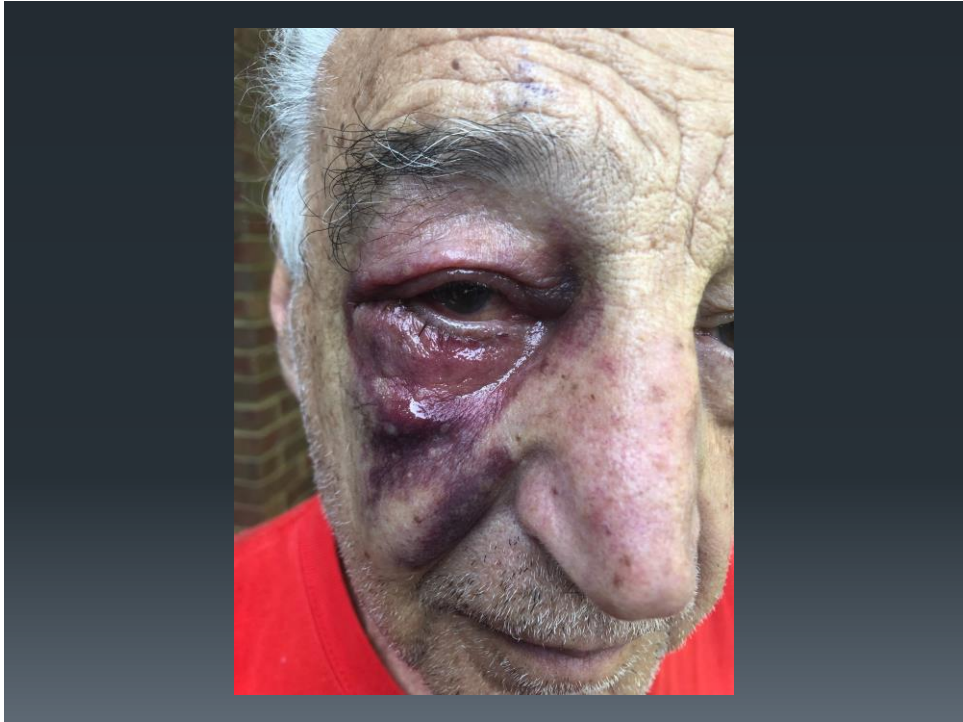
33

Published July 15, 2019  
Turning Inward  
Brush up on the treatment options for involution entropion.  
Edited by Paul C. Ajamian, OD

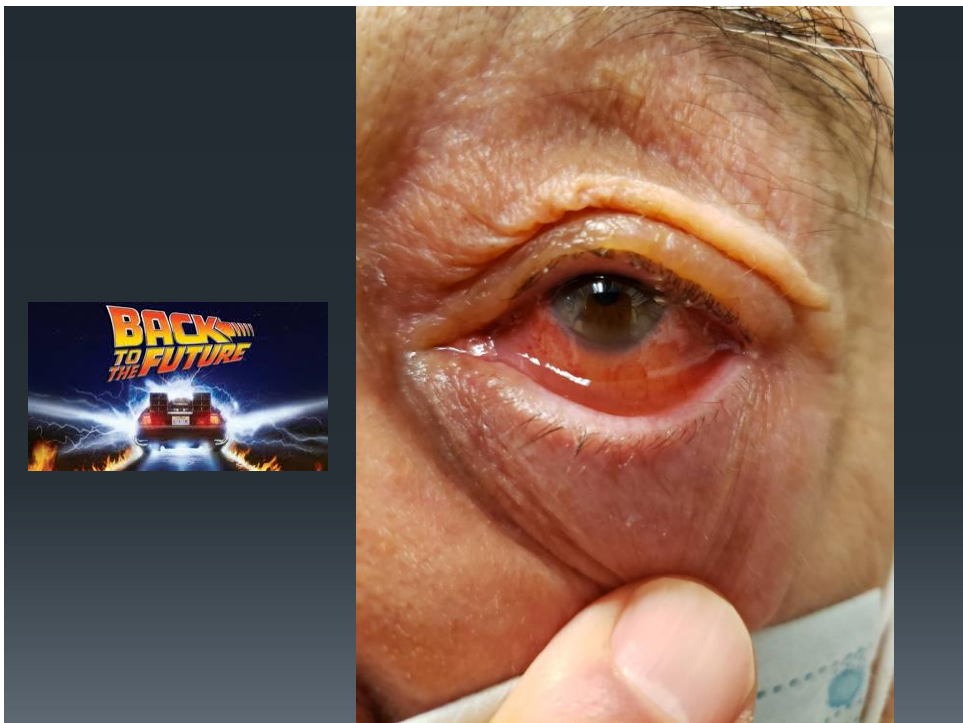**Q:**  
I have a patient with significant entropion and lashes contacting the globe that are causing a great deal of discomfort. Artificial tears aren't helping. What are some short- and long-term solutions?



34



35



36

## Findings from his front porch:

- NO PAN
- 4 + diffuse injection, watery discharge
- Major lid swelling
- A lot of pain
  
- “I take Amoxicillin for my recurrent sinus infections”

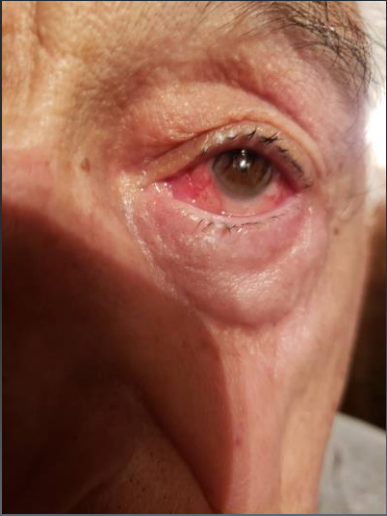37

## Fear Factor: What am I Missing? What's the Treatment?

- STEP BY STEP!
  - NO PAN SO NO EKC?
  - SINUS INFECTION SO COULD BE RELATED TO THAT
  - AUGMENTIN WORKS SO LETS TRY THAT: BUMPED UP TO 500 TID FROM BID
  - JUST BECAUSE EYE LOOKS HORRIBLE DOESN'T MEAN I CAN'T HANDLE IT, AS LONG AS IT IS GETTING SLIGHTLY BETTER EACH DAY!

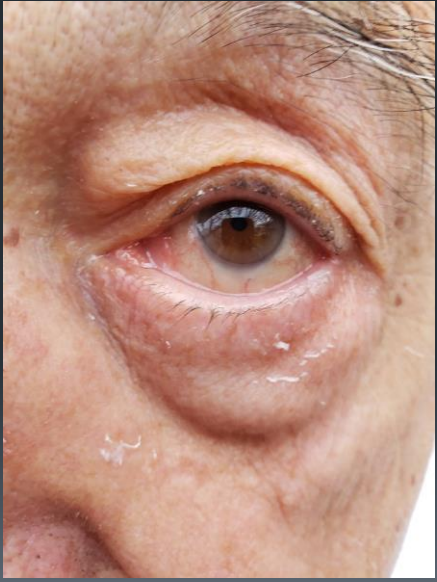
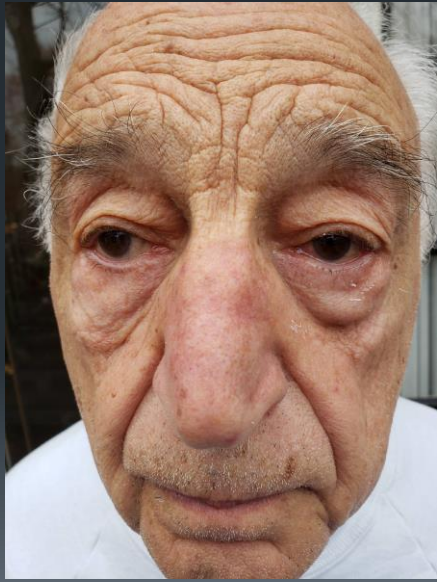38

Day 2 Pain Better  
Day 4 below: "Much Better"

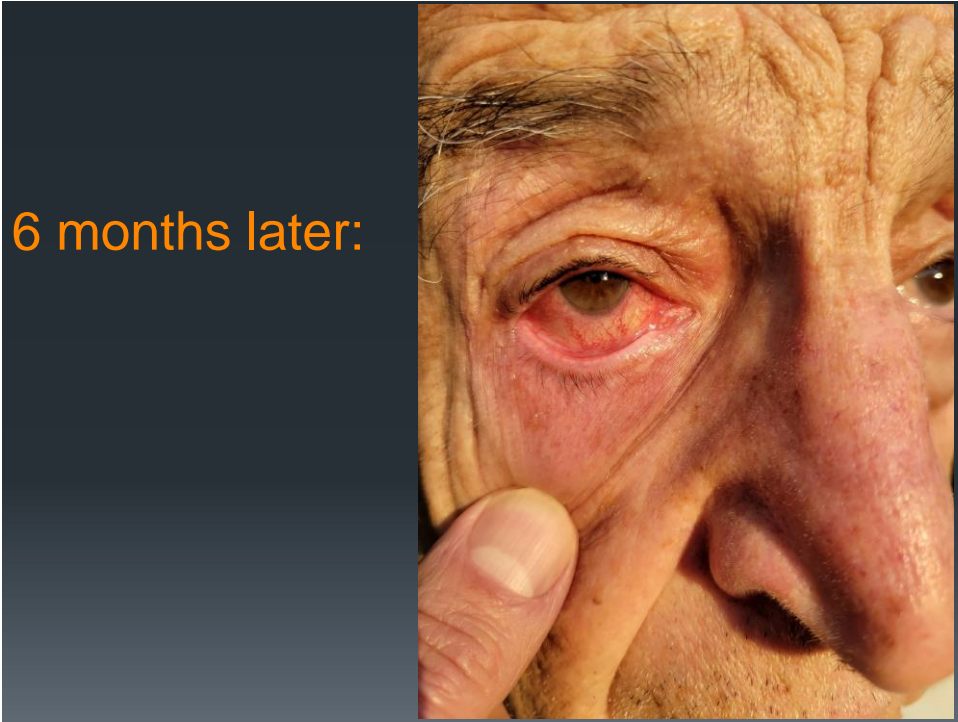


39

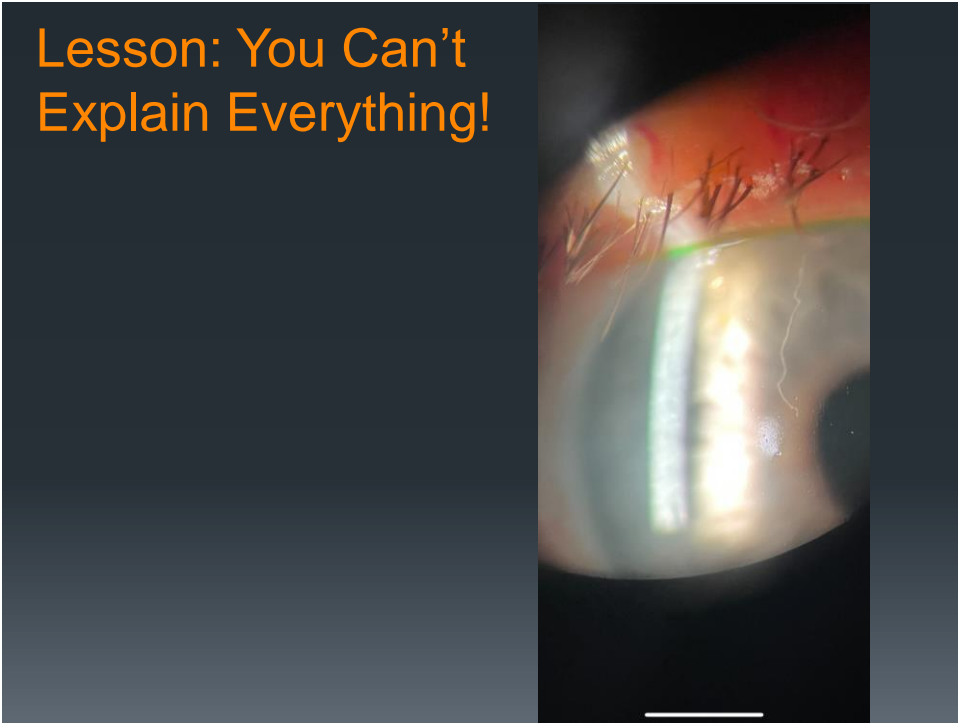
Not sure what it was...but all better  
DAY 8!



40

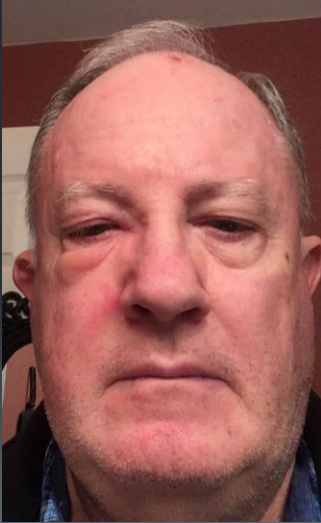

41



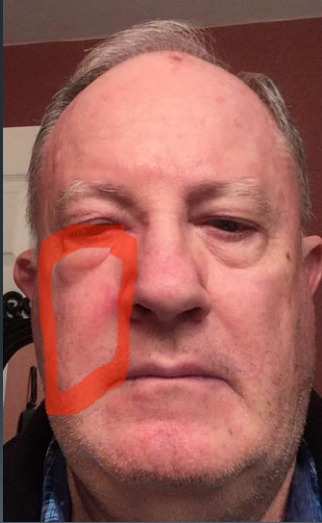
42

# Another Unexplained Preseptal Cellulitis



43

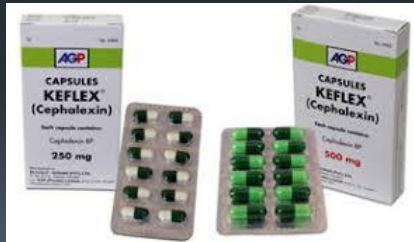# ENT CONSULT



44

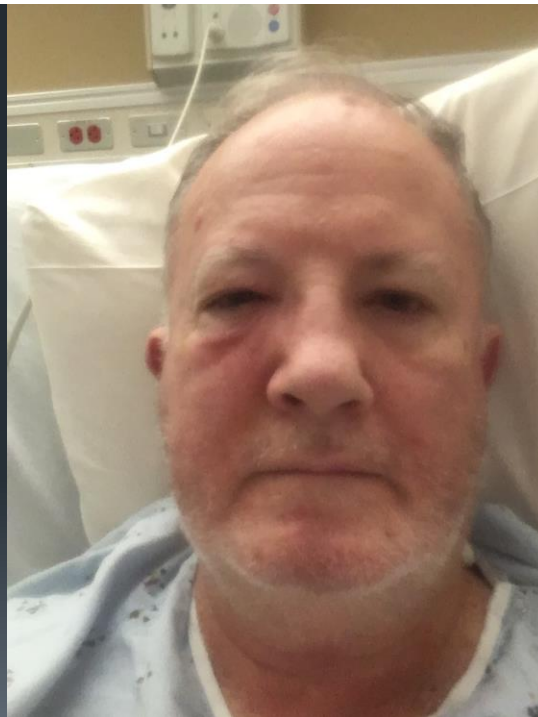## ENT INITIAL RX

- KEFLEX 500 QID



45

- Getting worse so.....
- Hospitalized (during COVID) for 5 days with IV antibiotics:
- STILL NO IMPROVEMENT



46

Gets out of hospital, ENT at a loss, sends him to orbital specialist who sends him back to ENT

He calls his OD

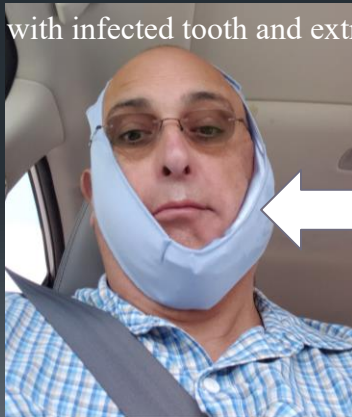Who refers him to us (did I mention during Covid!)



47

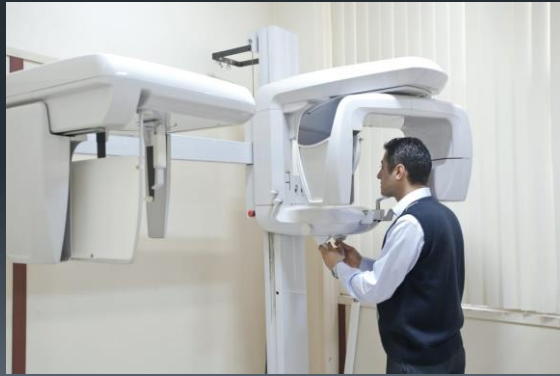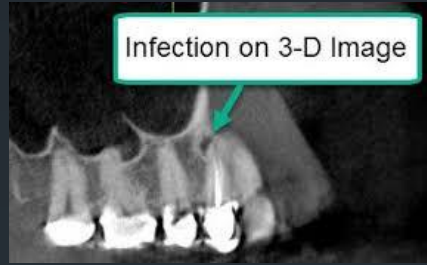Back to our dude....I referred him to a dentist, but why?

Me a month earlier with infected tooth and extraction .....during Covid!



48

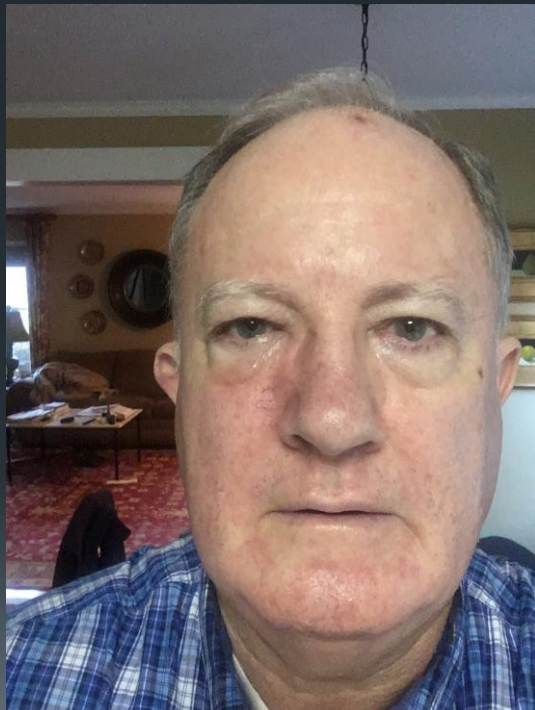Sent him to his Dentist  
who ordered a  
Cone Beam CT



49

A Tooth for an  
Eye:

3 days after  
tooth  
extraction:  
much better!



50

When you are in a Quandary:  
CALMLY ASSESS vs  
*“Let’s just get it out of the  
office!”*

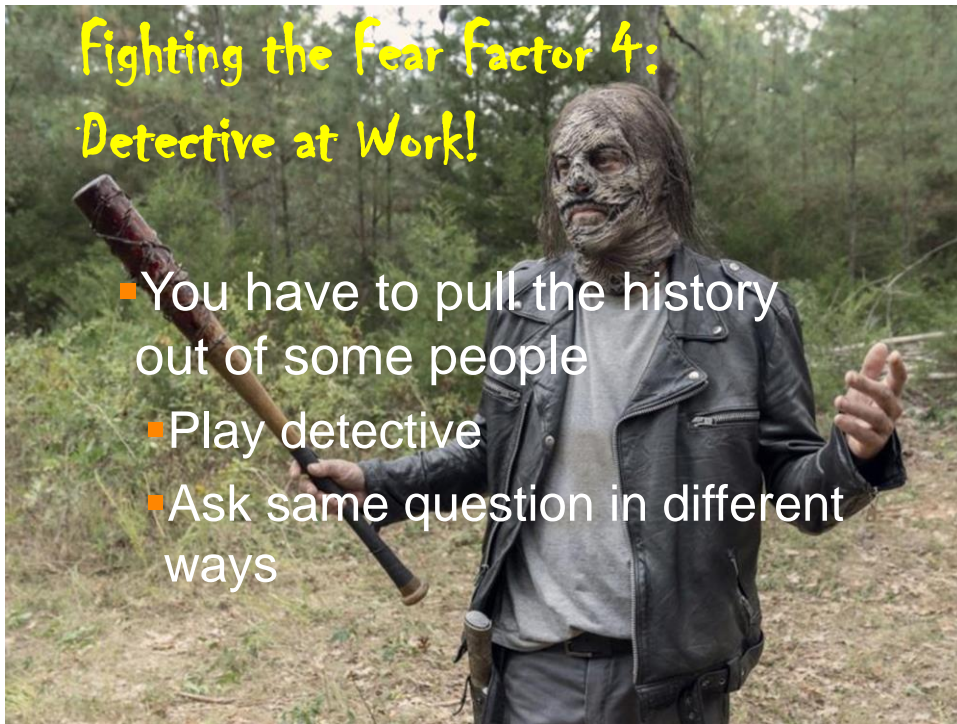


51

Calmly assess the eye one test  
at a time.

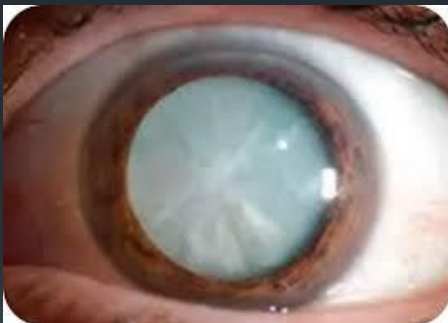- AND KNOW YOUR ORAL MEDICATIONS, HAVE A PLAN FOR ANTIBIOTICS, ANTIVIRALS AND PAIN MEDS
- HAVE A DEA NUMBER AND KEEP IT ACTIVE!

52



53

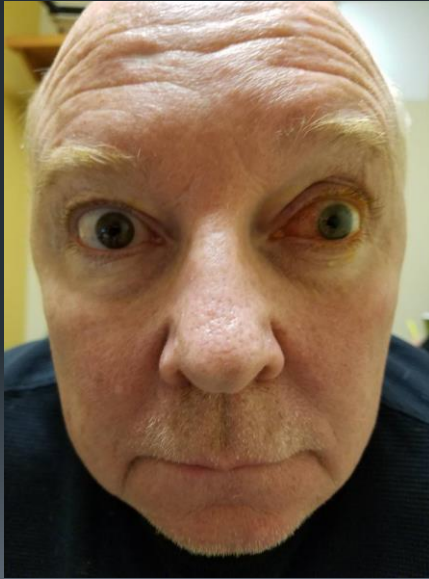
## 39 yo male with “sudden onset” VA loss



- Any trauma? NO
- Any injury to the eye? NO
- Been hit in the eye? NO
- Have you ever been in a fight?
- “Oh yes hundreds of fights, I just got out of prison”

54

“I Have Pink Eye”!



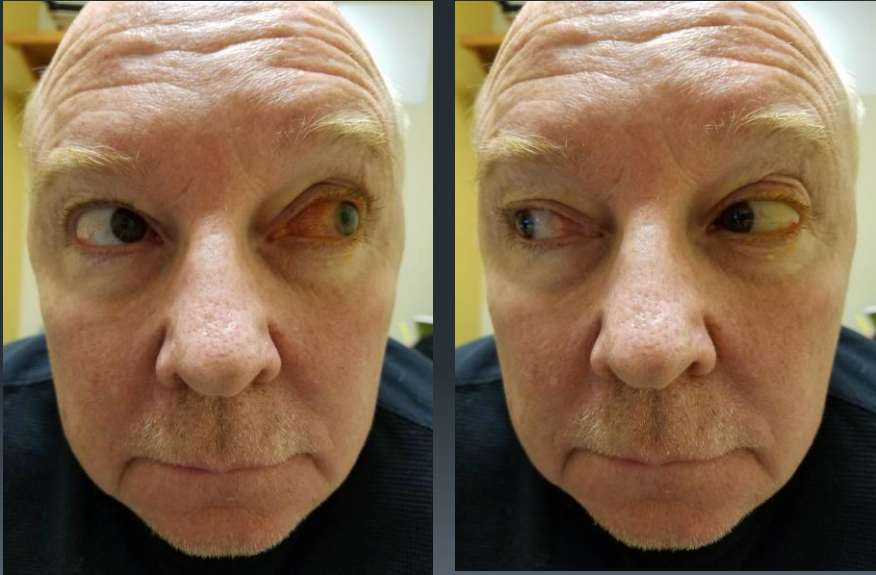55

## 67 WM

- s/p Vivity Toric IOL OS 9/26/20
- Day 1: 20/20 and J1
- Day 14: Comes in for second eye surgery  
OS: still 20/20 and J1

56

GET THE BIG PICTURE, UP DOWN LEFT RIGHT



57

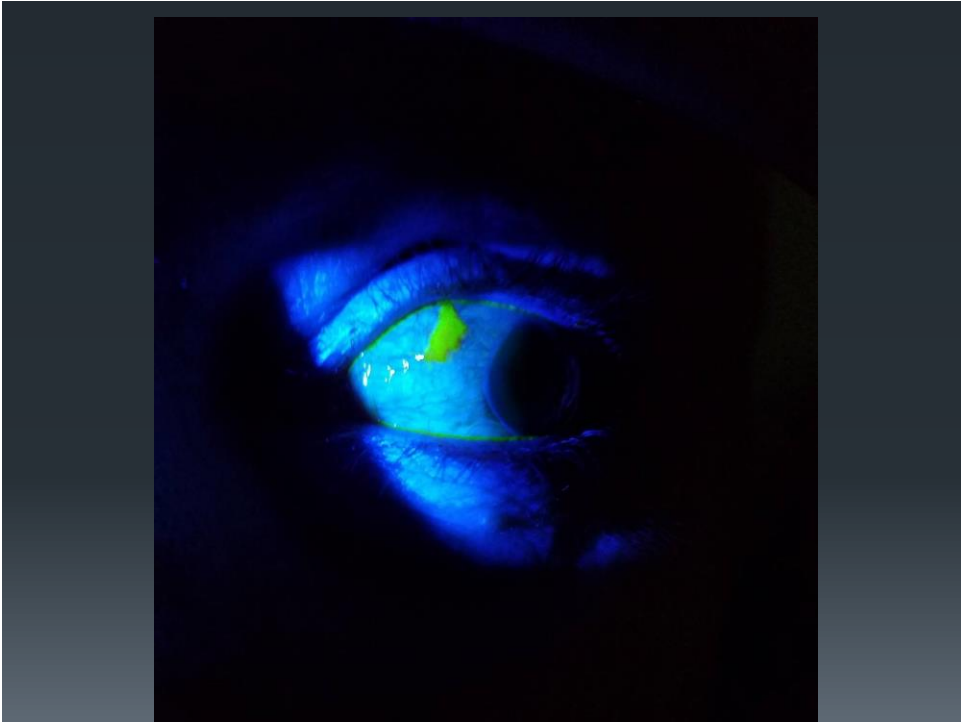
Your tentative diagnosis on this patient with sector injection:

- A. Episcleritis
- B. Scleritis
- C. Rebound iritis after cataract surgery
- D. Conjunctival abrasion

58

# Poll Question 3

59



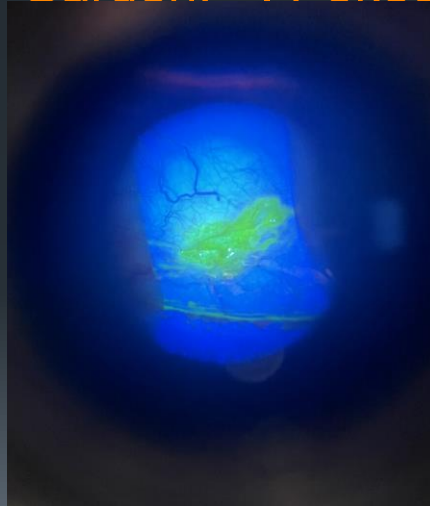
60

## More history?

- Any injury to the eye? NO
- Oh, maybe I felt something Sunday working in the yard
- Oh, wait, I was walking the dog and ducked through some bushes and a branch hit my eye!

61

## Emergency Call from Wife Susan from the Garden! "I Poked My Eye"!



62

## Lesson learned

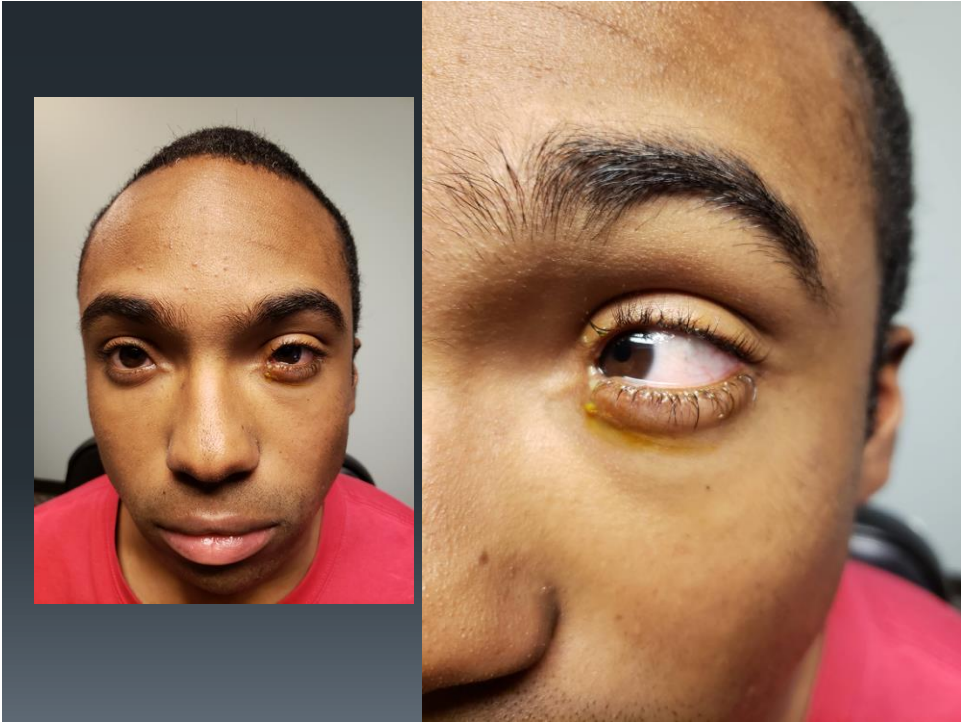- Have to be curious and dig deep
- Episcleritis is rare, scleritis is rarer
- Conjunctival abrasions are common and even more commonly misdiagnosed!
- Antibiotic, not steroid therapy

63

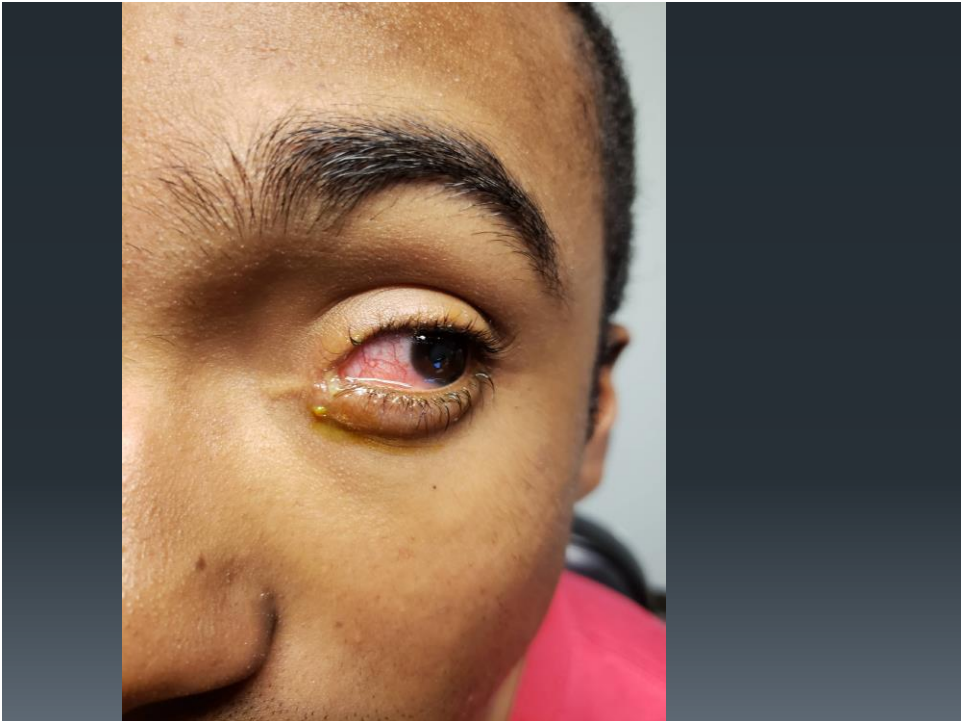
## 22 Male with “NO HISTORY” of anything that would explain his 3 week pink eye

- Sees OD, given Tobradex which stings
- Changed to Vigamox a week later due to no improvement
- Eventually sent to Omni

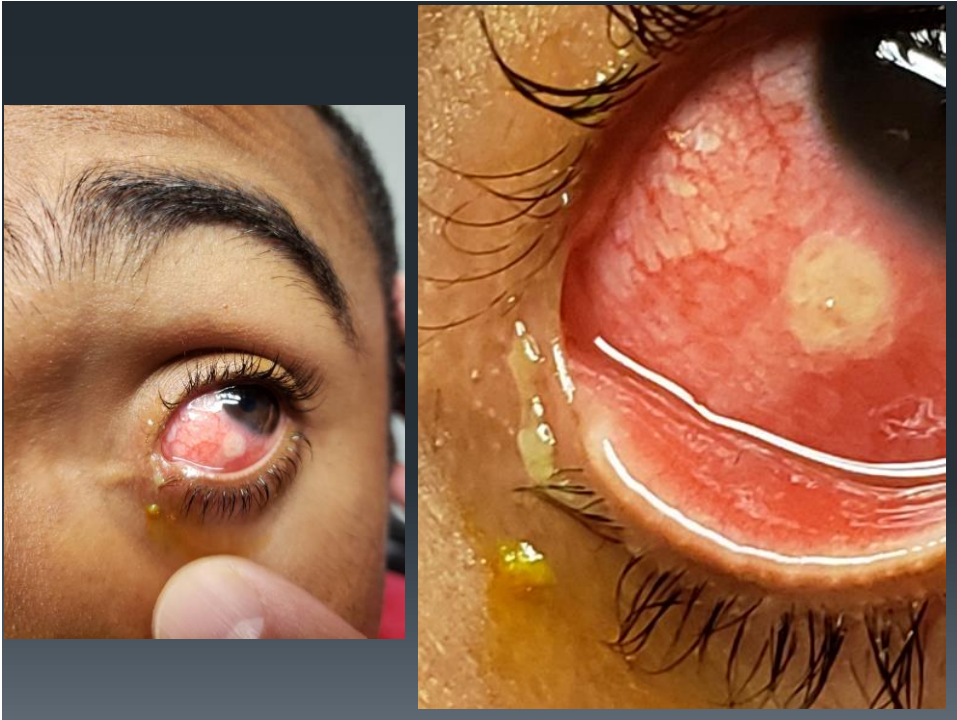64



65



66

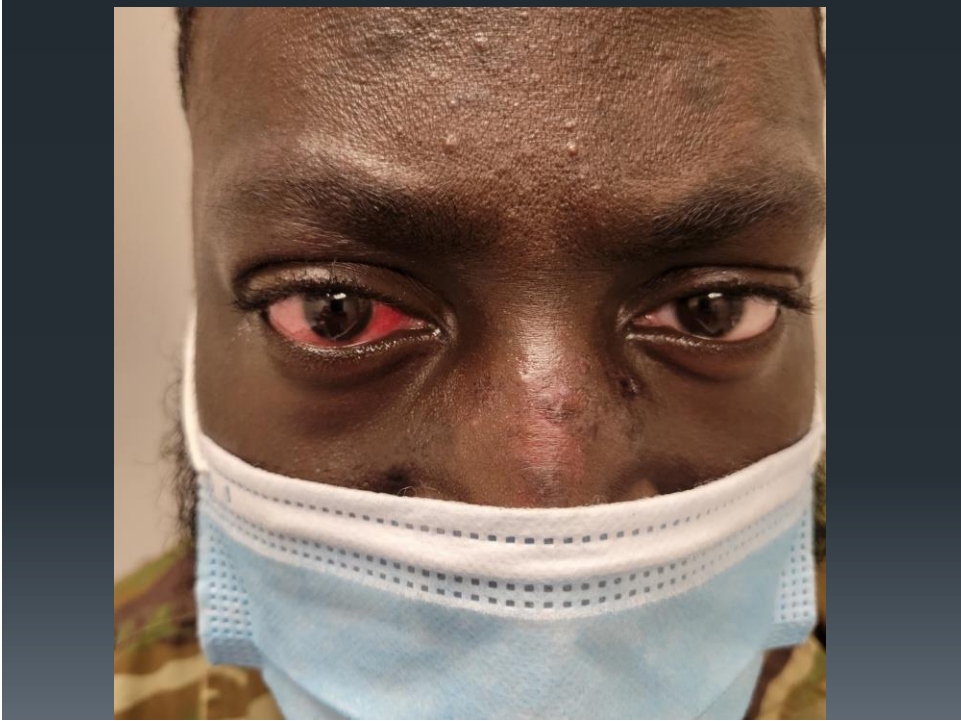

67

## Speaking of sector injection....

- 29 BM presents 5/27/22 after being treated for 3 days with Pred Acetate QID

68



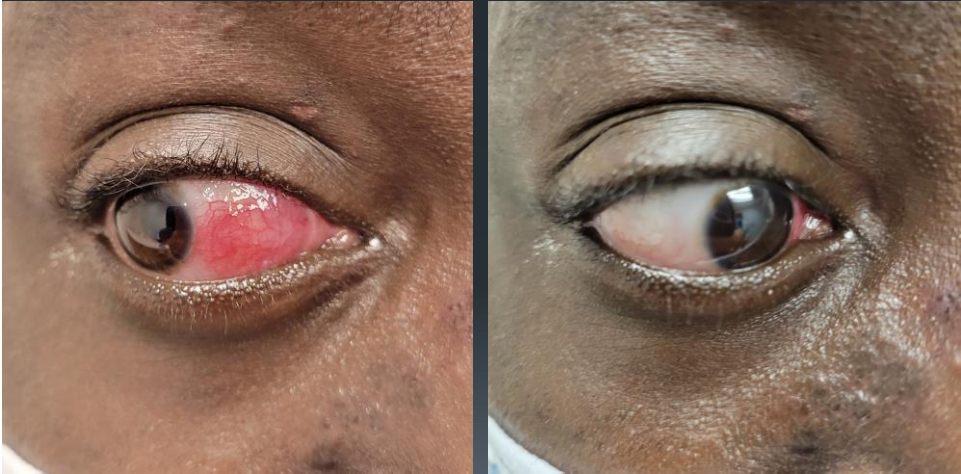69

Basics: look at eye in all POGs

Two side-by-side close-up photographs of the same person's eyes, showing the redness from different perspectives. The left image shows the eye from a slightly lower angle, while the right image shows it from a slightly higher angle. Both images clearly show the red, inflamed sclera. The person is wearing the same blue surgical mask as in the previous image.

70

One drop 2.5% Phenylephrine



71

# Poll Question 4

72

## You have to pull the history out of MOST people!

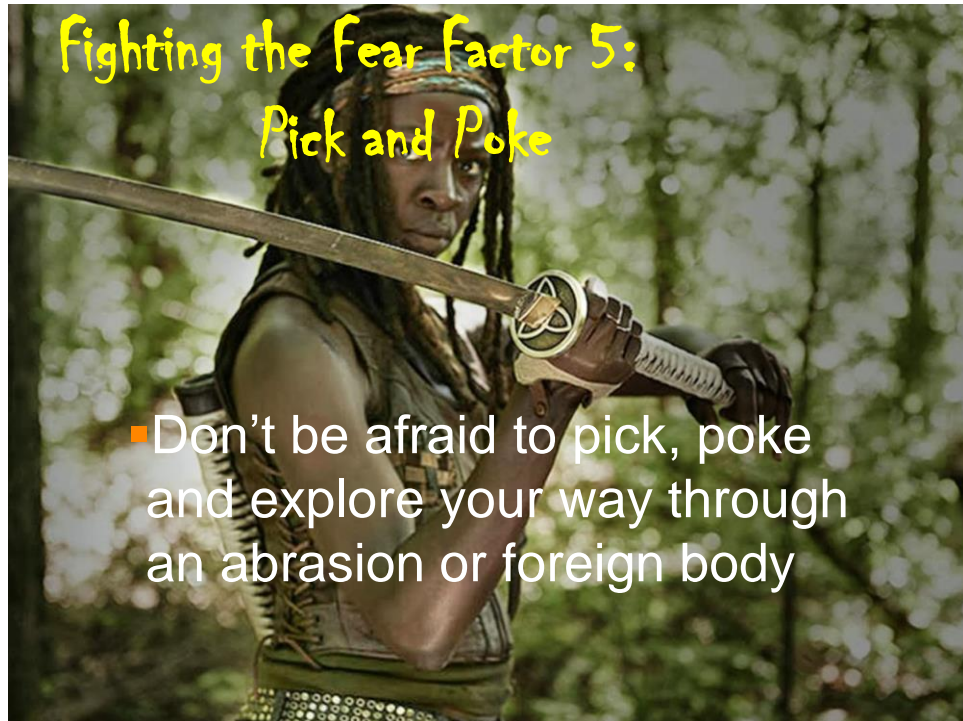- NO ONE GIVES UP HISTORY TOO EASILY SO BE PERSISTENT, ASK THEM IN DIFFERENT WAYS, AND INVOLVE FAMILY MEMBERS
- RECENT CASE "I AM HERE FOR CATARACT SURGERY"



73

## Fighting the Fear Factor 5: Pick and Poke

- Don't be afraid to pick, poke and explore your way through an abrasion or foreign body



74

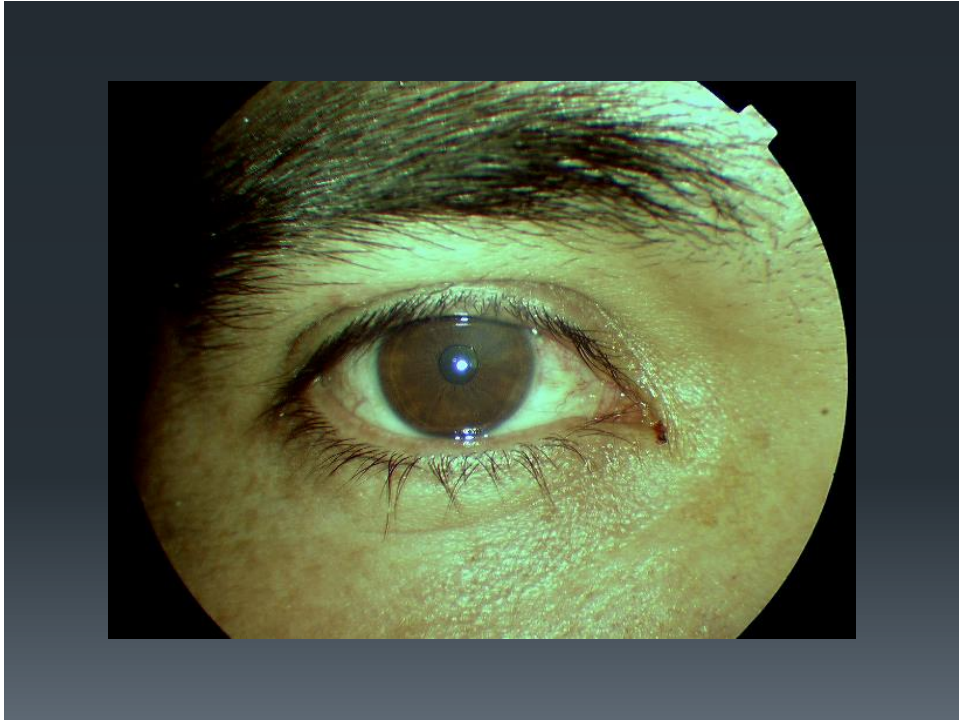
## Anyone Seen the Metal?

- 23 yo non-English speaking Hispanic Male
- Roofer by trade
- c/o slight foreign body sensation OD for 1 week
- Was hammering and “something flew into eye and did not come out”

75

- Seen by an emergency medical center
- Told he had an infection and abrasion and was given Polytrim
- Seen by doctor the next day, “nothing found”
- “no pain”

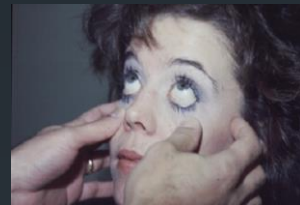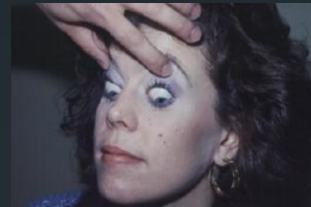76



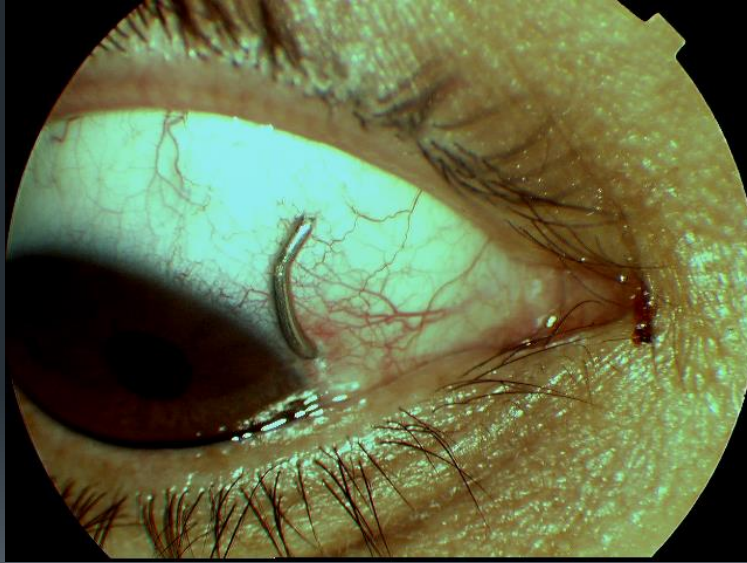
77

## Before you panic and refer:

- All red eyes get three extra tests besides a thorough history:
  - Get the big picture by having patient look up down left and right
  - Check for preauricular nodes
  - Evert lids



78



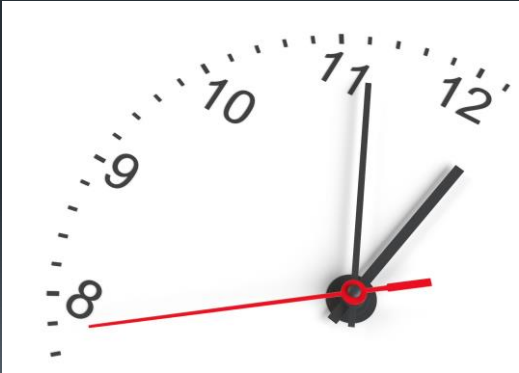
79

## Corneal Foreign Bodies

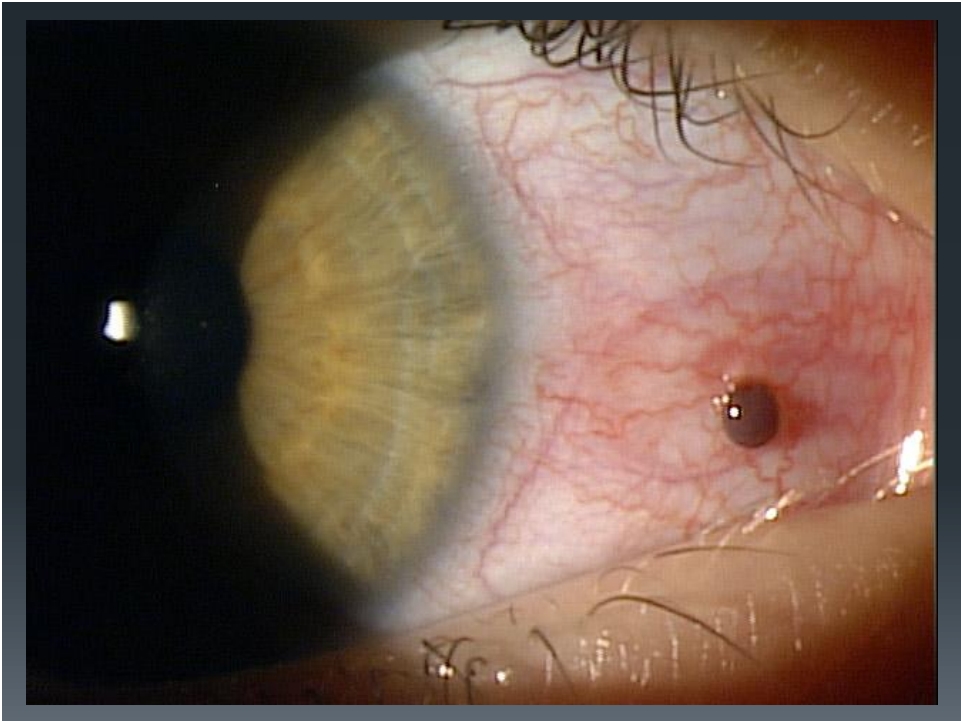
- Types: Metal, plastic, organic, and unknown
- They often want to know what it is that you took out.....be prepared!

80

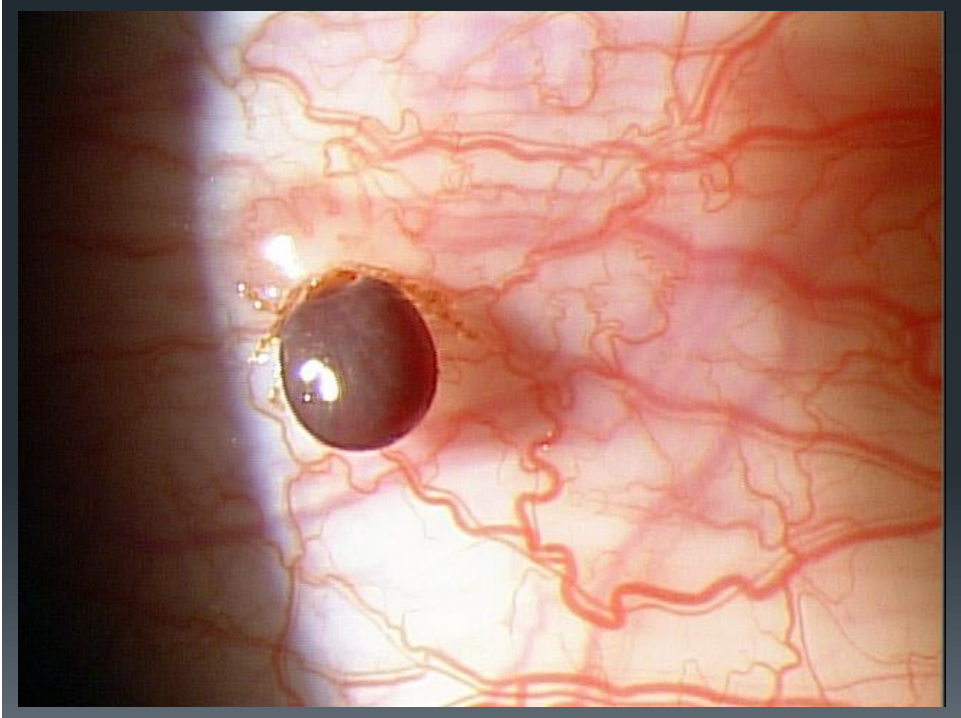
Tick, tick, tick



81



82



83

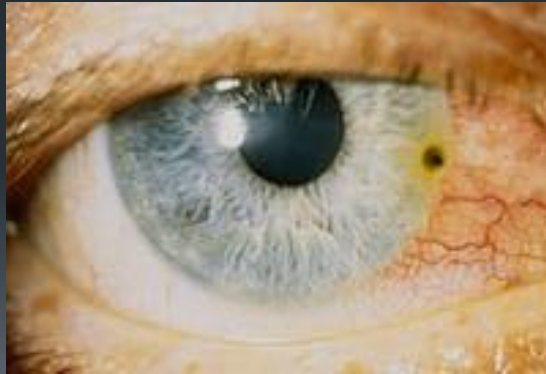### “Reasons” not to take it out?



- “Deep”
- “On Visual Axis”
- Patient in pain
- Don’t know what it is

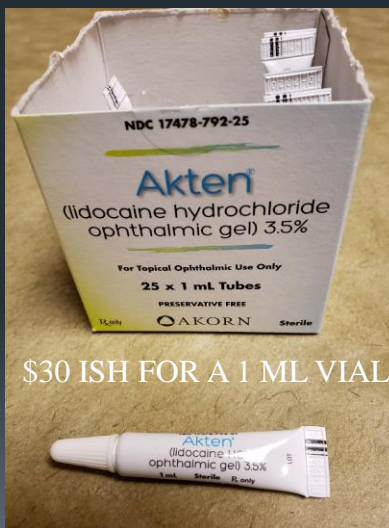84

Limbal FB's the toughest!



85

ORDERING: YOU MAY NEED TO  
GOOGLE AND SET UP AN ACCT



\$30 ISH FOR A 1 ML VIAL

- Accutome/Keeler
- Hilco Vision
- Amcon Labs
- Medline
- McKesson

86

Be a picker poker and explorer!

stephensinst.com/product/jewelers-forceps-3c-straight/

**STEPHENS INSTRUMENTS**

Products Eye Banking Services About Contact

**\$29.99**

Jewelers Forceps, #3C, Straight

Overall Length: 111.5mm

To view pricing, please login or create an account.

SKU: **55-1700**  
Categories: Forceps, Suture

PRODUCT SEARCH

Search...

PRODUCT CATEGORIES

- > Blade Breaker (4)
- > Brush (6)
- > Caliper (7)
- > Cannula (33)
- > Chopper (12)
- > Curette (14)

87

OR.....

IMS IMS-JF3 Premium High Precision Jeweler Style Forceps #3 Tweezers, Fine Point Tips, Stainless Steel, 4.5" L

Brand: IMS

3.9 ★★★★★ (51) | Search this page

**\$6.99**

prime One-Day FREE Returns

FREE delivery **Tomorrow, May 1** to [Roswell 30075](#)

1 delivery sustainability feature

**In Stock**

Quantity: 1

**Add to Cart**

**Buy Now**

Ships from Amazon  
Sold by IMEDS

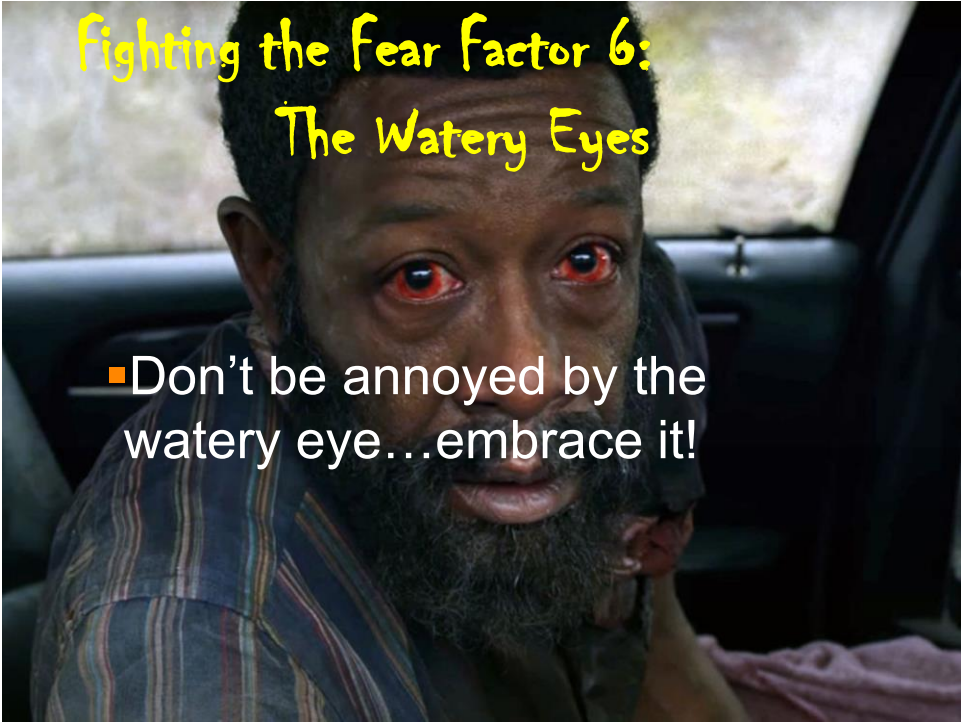Roll over image to zoom in

Ask Rufus

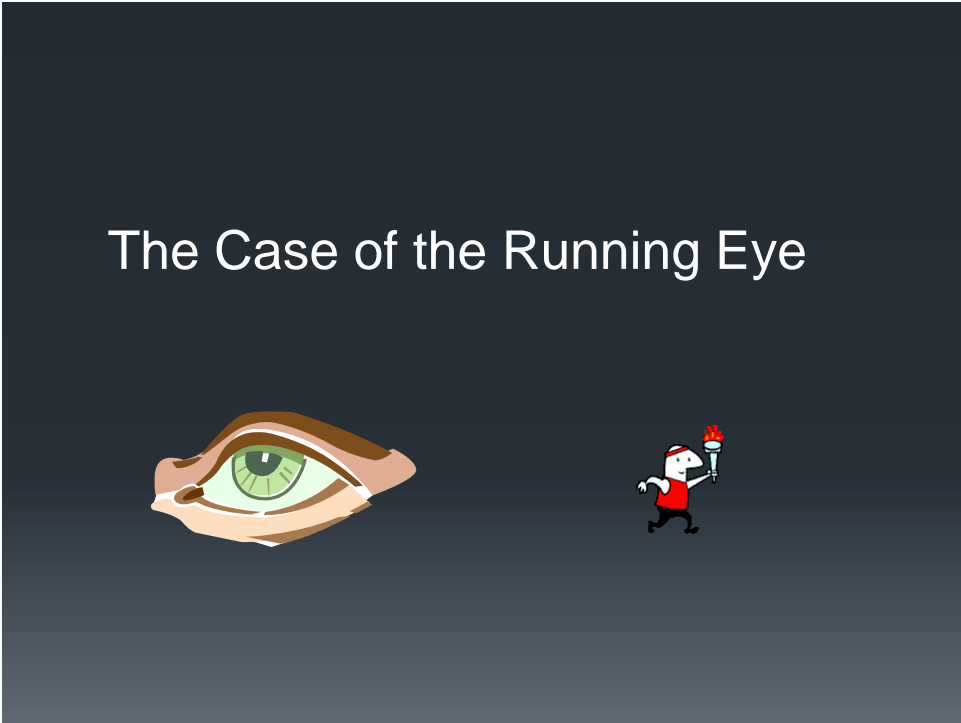
**About this item**

Brand	IMS
Material	Stainless Steel
Color	Silver
Style	Fine
UPC	696950730106

88



89



90

- 41 WF
- Breast cancer survivor
- Worried about itching and “tearing” OS > OD, worse when “out of contacts”

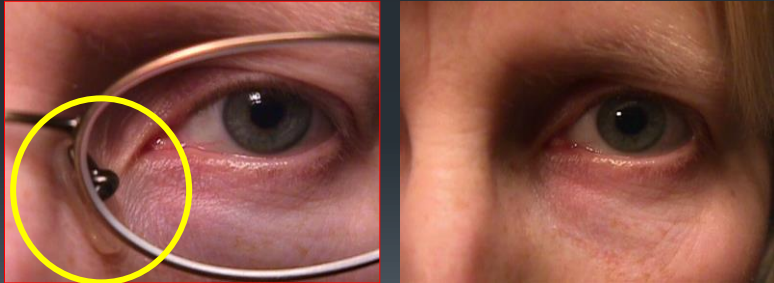


91

## **Poll Question 5**

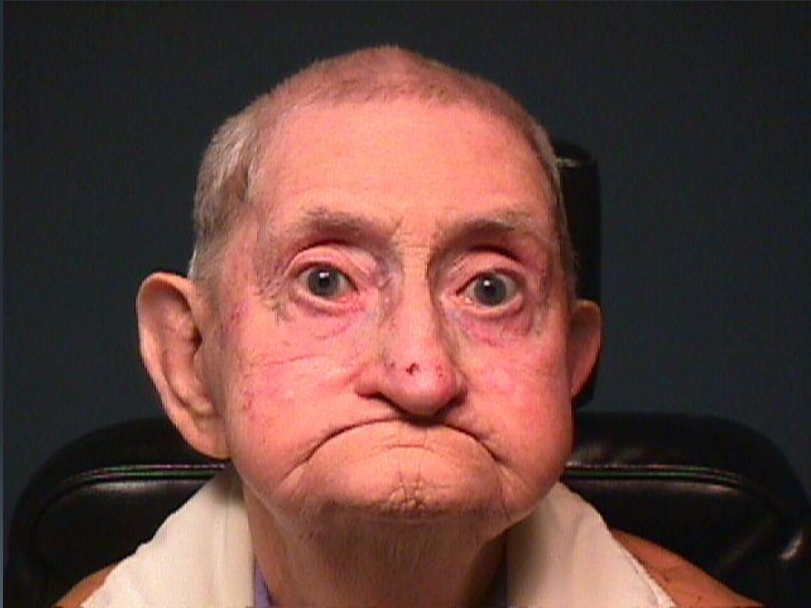92

Before and after

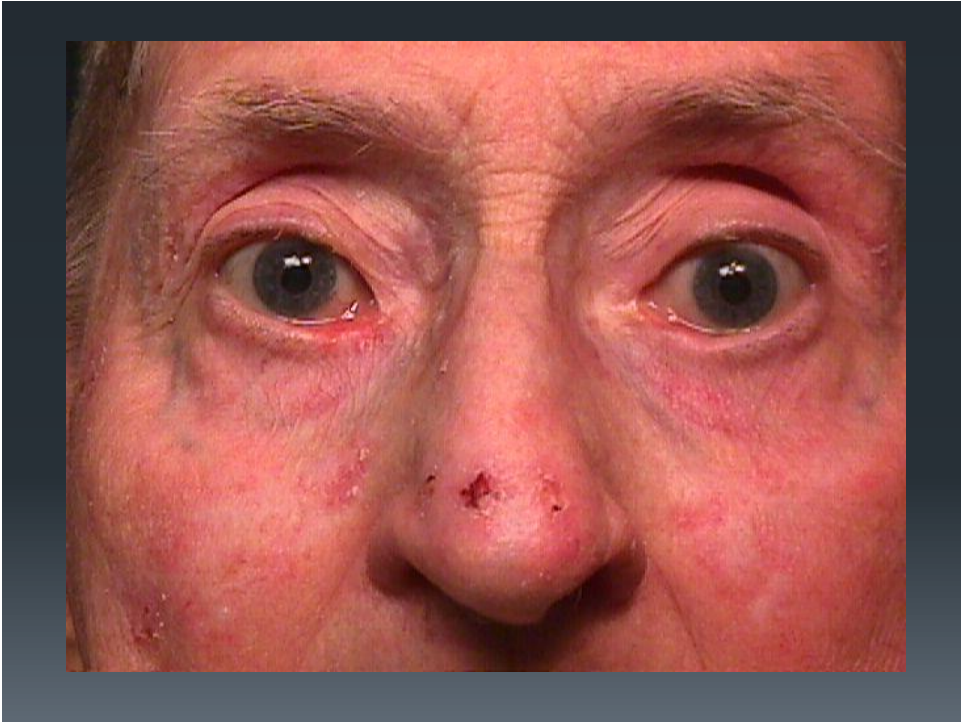

AND HERE IS THE CULPRIT!!

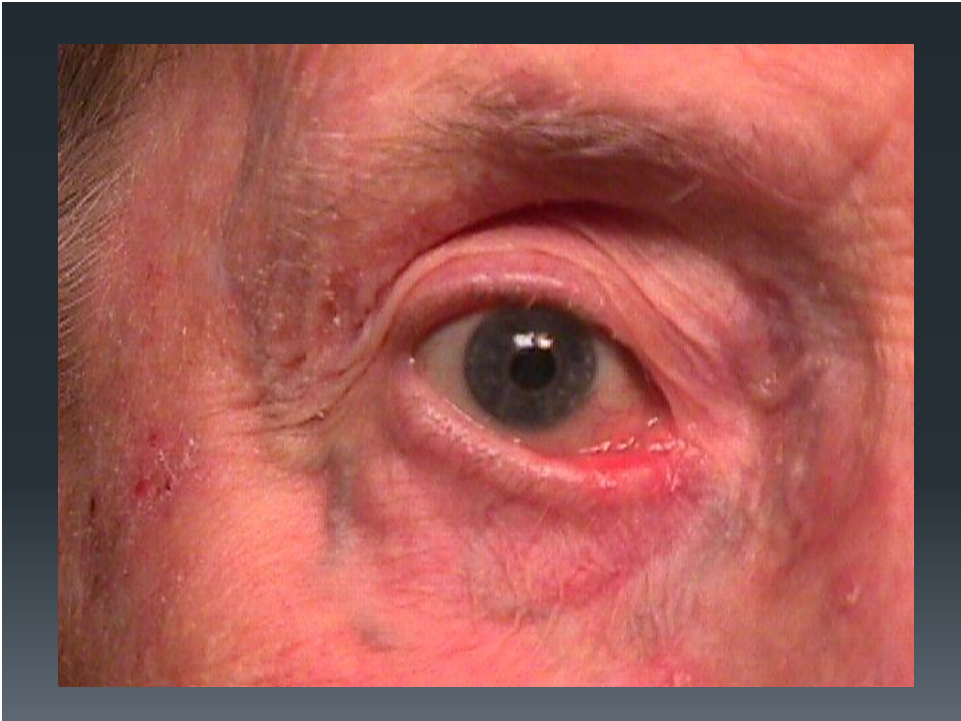93



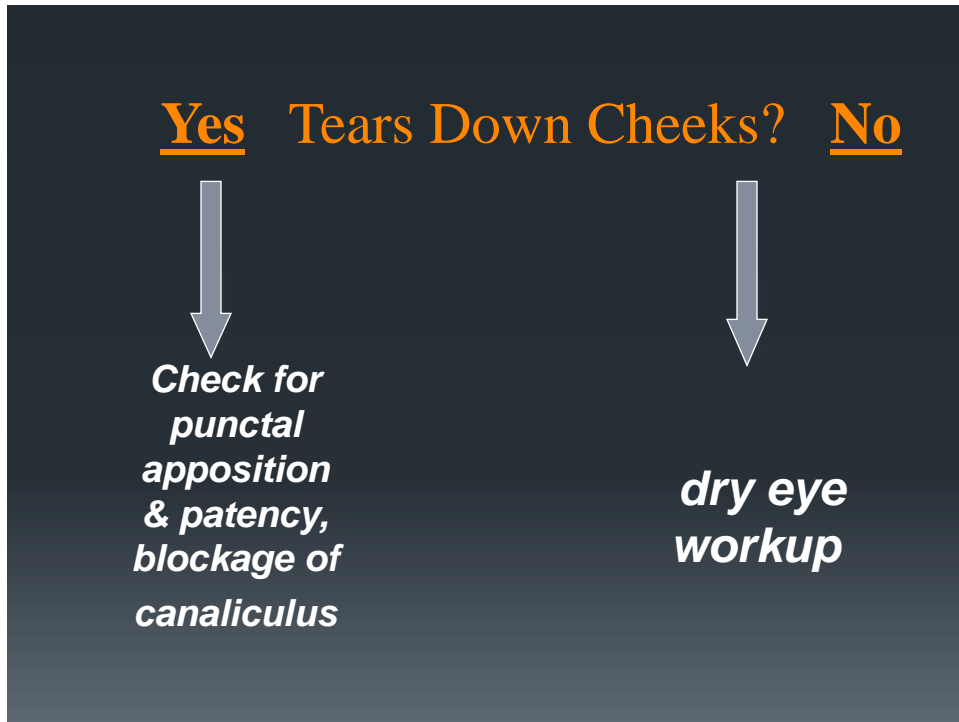
94



95



96

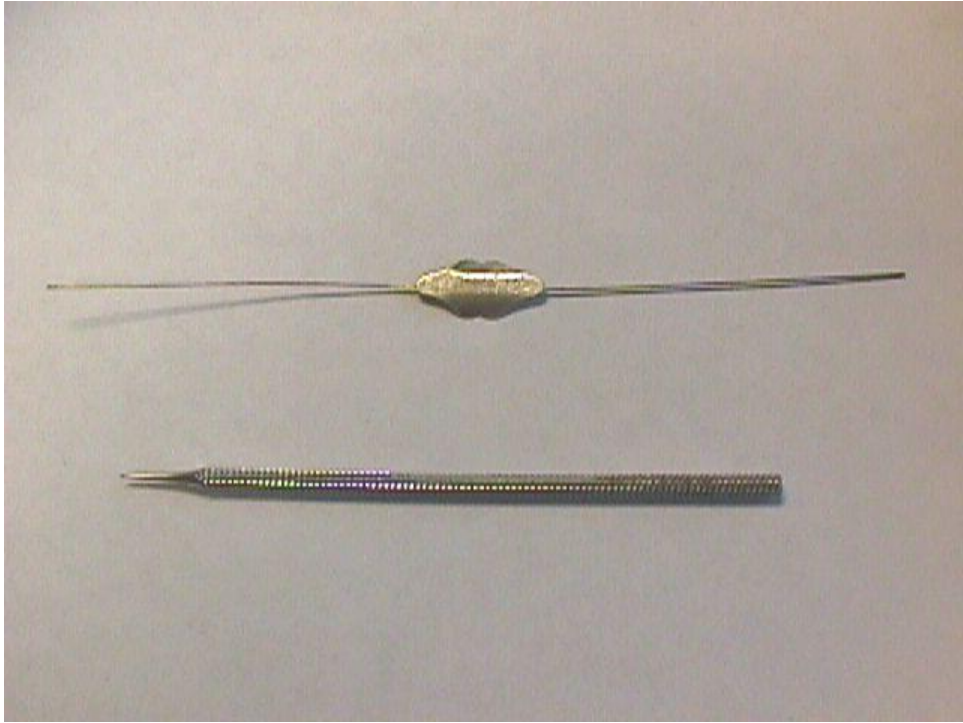


97

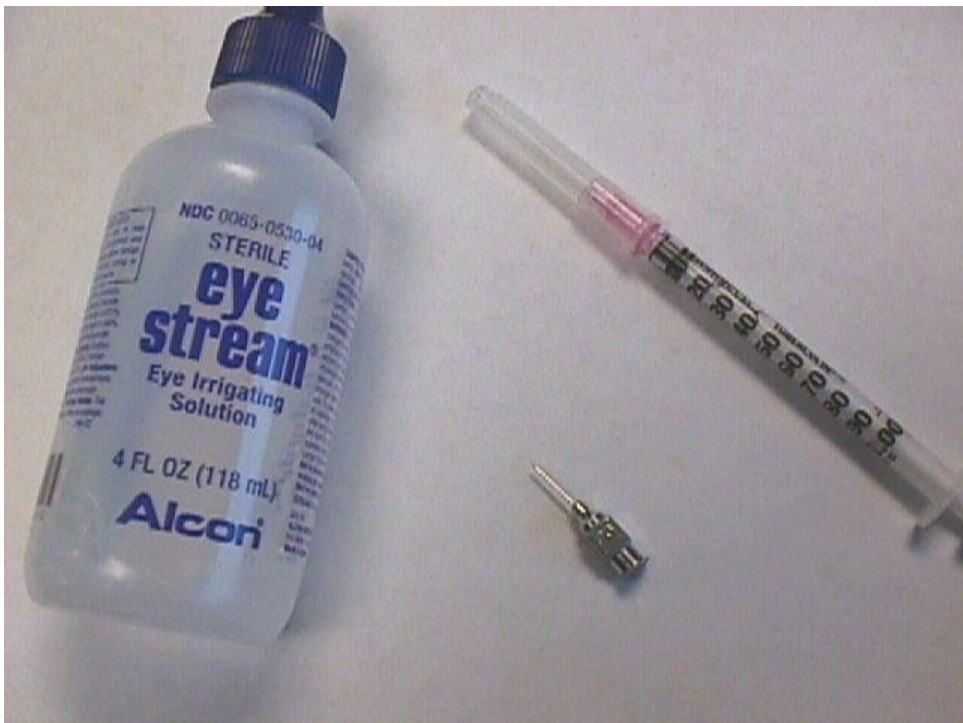**True epiphora**

- examine punctal openings (size and apposition to globe), then dilate/irrigate to determine site of blockage

98



99




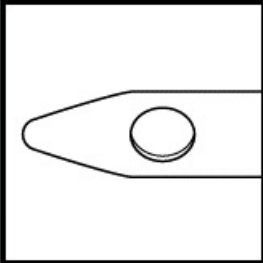
100



101

## Irrigating Cannulas/Dilators

- Shahinian Lacrimal Cannula, straight (bullet tip 23 ga)



102

# Shahinian Lacrimal Cannula

**AMBLER SURGICAL** Cross-Reference Catalog # or Search by Description Q Contact Us: 1-888-407-0006 SIGN UP LOG IN W

BROWSE BY SPECIALTY ▾ BROWSE BY TYPE PRODUCT LINES ▾ STERILIZATION PRODUCTS ▾ REPAIR SERVICES ▾

TIP STYLE +  
MEASUREMENTS -  
OVERALL LENGTH +


<b>Shahinian lacrimal cannula, 23 gauge</b> , straight, blunt tapered tip, 0.3mm side port opening, 11.0mm overall ...	<b>Shahinian lacrimal cannula, 23 gauge</b> , straight, blunt bullet shaped tip, 0.3mm side port opening, 11.0mm ...	<b>Shahinian lacrimal cannula, 23 gauge x 1/2"</b> , 0.3mm aspiration port, smooth bullet shape tip, packaged ...
\$81.00 <span>Add to Cart</span>	\$87.00 <span>Add to Cart</span>	\$63.00 <span>Add to Cart</span>

Need help?

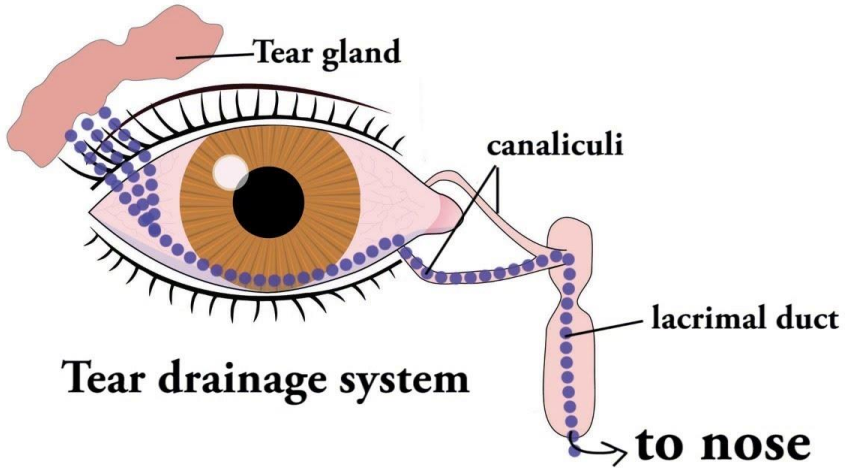
103

# Burnstine cannula

- Combination dilator/irrigator
- Katena.com

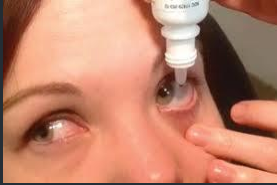
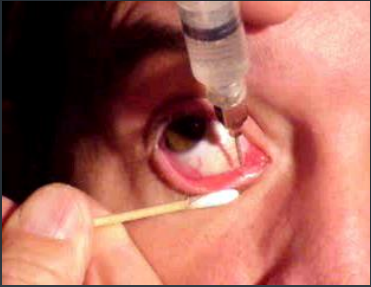
104



105

### Irrigation



106

## Take Home Pearl

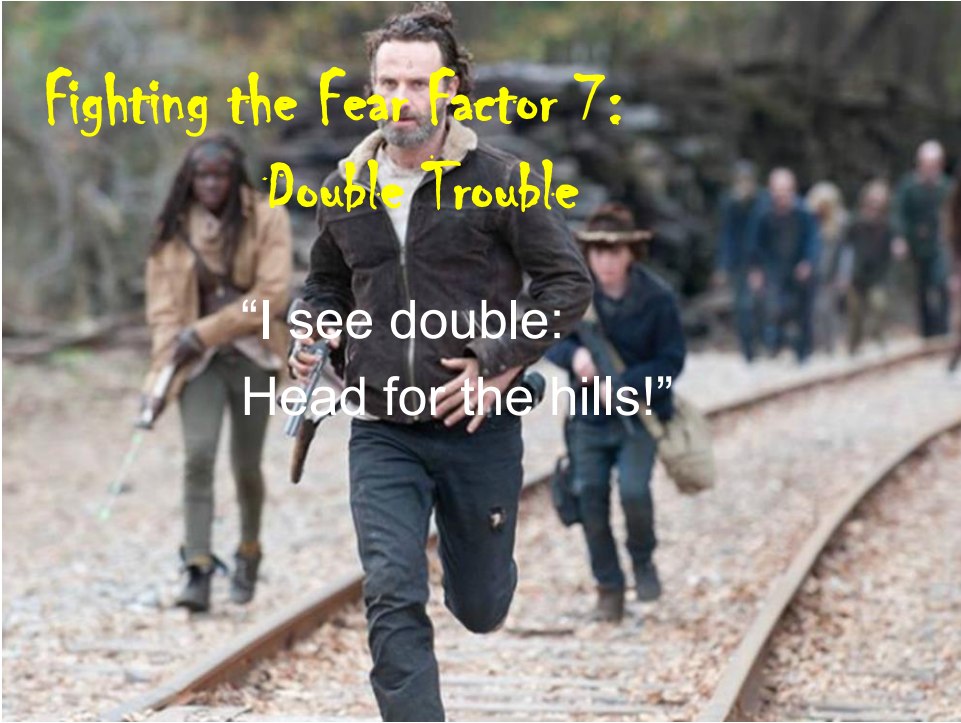
- **Always ask about tearing...”do the tears run down your face?”**
- **Think about adding lacrimal procedures to your practice!**

107

**“Runny Eyed” patients no longer need to be feared!**



108

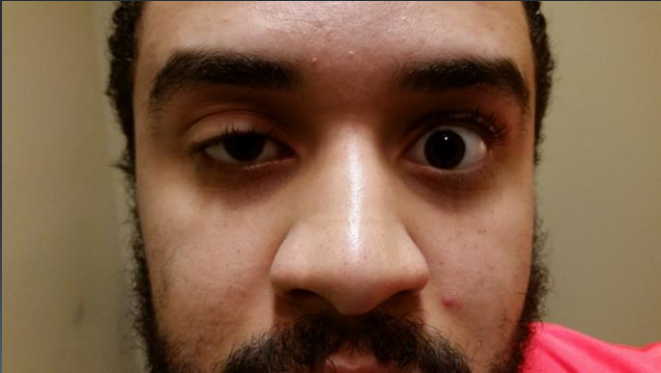

109



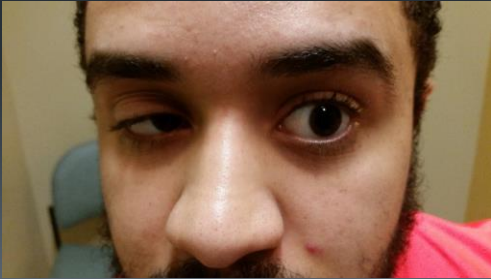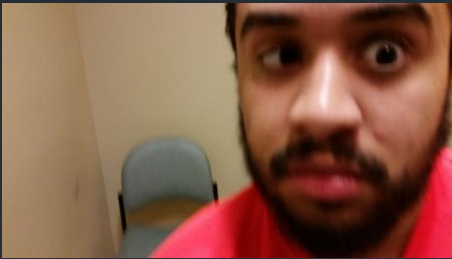
110

# 22 HM with "swollen lid"



111

# Motility Restriction



112

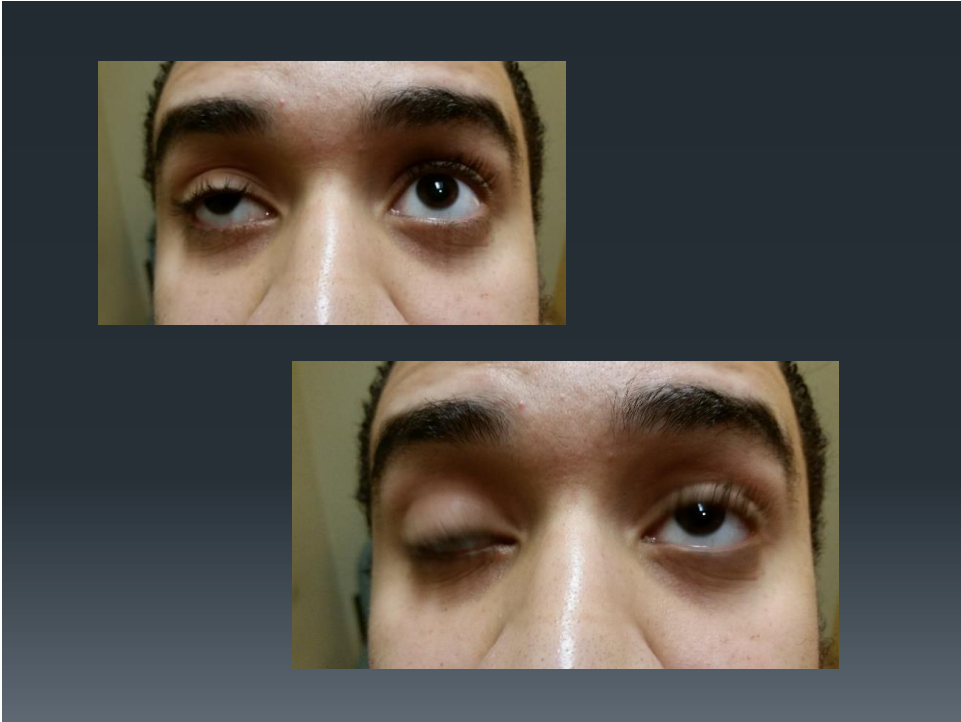## Poll Question 6

113

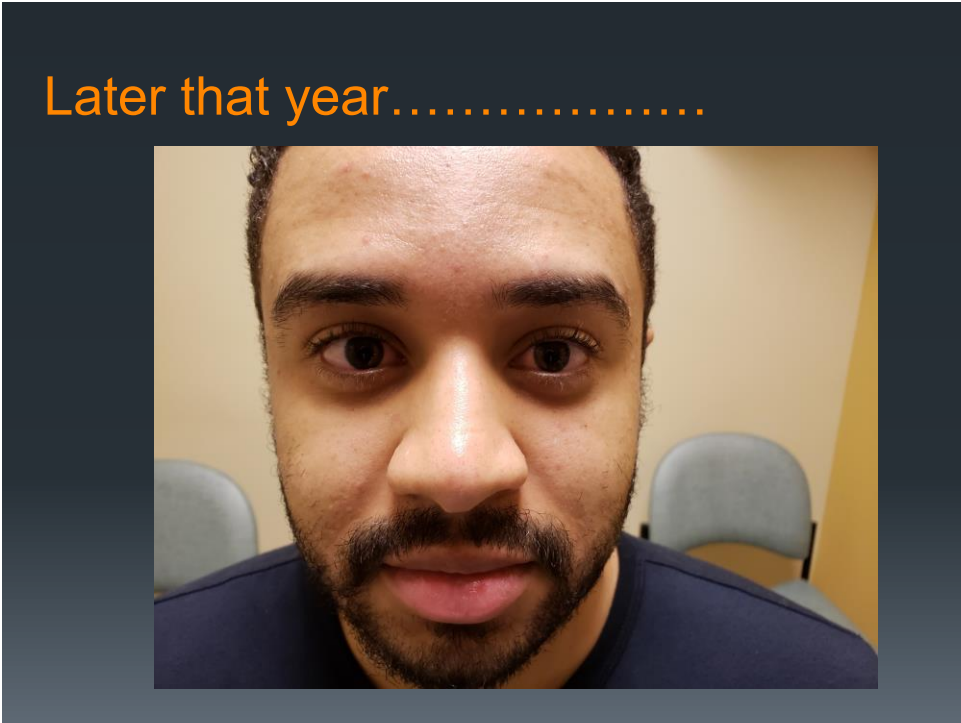
### Your tentative diagnosis:

- Left 6<sup>th</sup> N Palsy
- Duane's retraction syndrome
- Myasthenia Gravis
- Thyroid Eye Disease

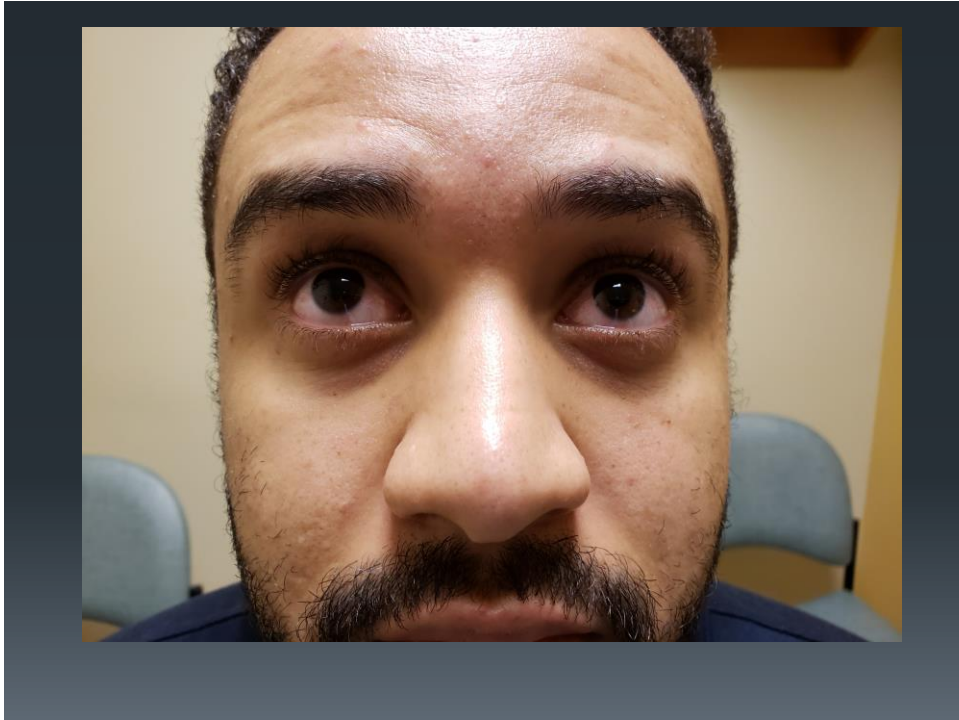114



115



116



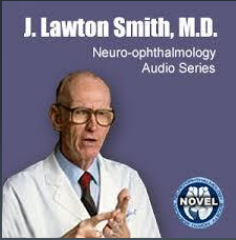
117

## Quick Facts

- MG may mimic any EOM palsy
- 75% of pts have ocular symptoms initially
- This is a neurological disease
- Treatment with anticholinesterase agents may not be effective>>>switch to steroids
- Consider thymus gland

118

# “New onset vertical diplopia in an adult is Myasthenia Gravis until proven otherwise”



119

# Search “Parks 3 Step Calculator”

## Parks Three Step

Superior Rectus (RSR)		Superior Rectus (LSR)
Superior Oblique (RSO)		Superior Oblique (LSO)
Inferior Oblique (RIO)		Inferior Oblique (LIO)
Inferior Rectus (RIR)		Inferior Rectus (LIR)

---

Which eye is hyper deviated in primary gaze? Right Hyper Left Hyper

Right Gaze Left Gaze Is the vertical deviation greater in right gaze or left gaze? Right Gaze Left Gaze

Is the vertical deviation greater with right head tilt or left head tilt? Right Tilt Left Tilt

120

# Don't Fear Double Vision!



121

# Final Factor : Stay out of Hot Water



122

## Dilate Dilate!

- 54 F has cataract surgery, and a week later notes flashes and floaters....OD doing post- op did OPTOS but never dilated, 3 weeks later sees an OMD who dx RD, lawsuit pending
- 47 M with a red eye, treated for uveitis but never dilated. Vitritis leads to HM vision and final diagnosis of fungal endophthalmitis, lawsuit pending

123

## Make Appointments!

- 56 M Sudden vision loss OD 20/200 with swollen nerve

124

## What is your working diagnosis?

- Optic neuritis
- Papilledema
- Non arteritic ischemic optic neuropathy
- Arteritic ischemic optic neuropathy

125

## OD diagnosed “AION” and ordered lab work

- CRP, Sed Rate, Platelets
- BUT TESTING NEVER GOT DONE
- 5 days later, the left eye “went out”
- Lawsuit and trial

126

## EIGHT GREAT ways of fighting the Fear Factor (and keeping the lawyers away):

1. Be a good observer
2. Don't be afraid of stranger things
3. Calmly assess one finding at a time
4. Detective at work
5. Pick and Poke
6. Watery Eyes
7. Double Trouble
8. Final Factor: Stay out of Hot Water

127

## Thank You!

■ [DRAJAMIAN@GMAIL.COM](mailto:DRAJAMIAN@GMAIL.COM)

128