



## Impact of glaucoma medications on the ocular surface and how ocular surface disease can influence glaucoma treatment

Miriam Kolko<sup>a,b</sup>, Gus Gazzard<sup>c,d,e</sup>, Christophe Baudouin<sup>f,g,h</sup>, Sofie Beier<sup>i</sup>,  
 Françoise Brignole-Baudouin<sup>f,h,j</sup>, Barbara Cvenkel<sup>k,l</sup>, Fredrik Fineide<sup>m</sup>, Anne Hedengran<sup>a,b</sup>,  
 Anton Hommer<sup>n</sup>, Erik Jespersen<sup>o</sup>, Elisabeth M. Messmer<sup>p</sup>, Rachna Murthy<sup>q</sup>,  
 Amy Gallant Sullivan<sup>r</sup>, Andrew J. Tatham<sup>s</sup>, Tor Paaske Utheim<sup>m</sup>, Marijke Vittrup<sup>t</sup>,  
 David A. Sullivan<sup>u,\*</sup>

<sup>a</sup> Department of Drug Design and Pharmacology, University of Copenhagen, Copenhagen, Denmark

<sup>b</sup> Department of Ophthalmology, Copenhagen University Hospital, Rigshospitalet, Glostrup, Denmark

<sup>c</sup> Glaucoma Service, Moorfields Eye Hospital NHS Foundation Trust, London, UK

<sup>d</sup> UCL Institute of Ophthalmology, London, UK

<sup>e</sup> NIHR-Moorfields Biomedical Research Centre, London, UK

<sup>f</sup> Centre Hospitalier National d'Ophthalmologie des Quinze-Vingts, Paris, France

<sup>g</sup> Université Paris-Saclay, Versailles-Saint-Quentin-en-Yvelines, Paris, France

<sup>h</sup> Institut de la Vision, Sorbonne Université, Paris, France

<sup>i</sup> Royal Danish Academy – Architecture, Design, Conservation, Copenhagen, Denmark

<sup>j</sup> Faculté de Pharmacie, Paris Cité université, Paris, France

<sup>k</sup> Department of Ophthalmology, University Medical Centre Ljubljana, Ljubljana, Slovenia

<sup>l</sup> Medical Faculty, University of Ljubljana, Ljubljana, Slovenia

<sup>m</sup> Department of Medical Biochemistry, Oslo University Hospital, Oslo, Norway

<sup>n</sup> Department of Ophthalmology, HERA Hospital, Vienna, Austria

<sup>o</sup> Copenhagen, Denmark

<sup>p</sup> Department of Ophthalmology, Ludwig-Maximilians-University, Munich, Germany

<sup>q</sup> Face Restoration, London, UK

<sup>r</sup> TFOS, Paris, France

<sup>s</sup> Princess Alexandra Eye Pavilion and Department of Ophthalmology, University of Edinburgh, Edinburgh, UK

<sup>t</sup> Fight for Sight, Copenhagen, Denmark

<sup>u</sup> TFOS, Boston, MA, USA

### 1. Introduction

Glaucoma is a common disease with an increasing prevalence [1]. Ocular surface disease (OSD) is also common, and its prevalence is increasing [2,3], due in part to the adverse effects of topical glaucoma medications [4,5]. Given this glaucoma/OSD association, David A. Sullivan, MS, PhD (Boston, MA, USA) and Amy Gallant Sullivan (Paris, France) on behalf of the Tear Film & Ocular Surface Society (TFOS), and in collaboration with Miriam Kolko, MD, PhD (Copenhagen University Hospital & University of Copenhagen, Denmark), organized a one-day meeting which was held on Saturday, October 22, in Cernobbio, Italy. This meeting focused on the impact of glaucoma medications on the ocular surface, and how OSD can influence glaucoma treatment. The

term “ocular surface” encompasses the surface (cornea and conjunctiva), tear film, and adnexa (lacrimal and meibomian glands). The speakers included internationally renowned glaucoma and OSD experts. The evidence-based proceedings of this meeting are presented in this TFOS Experts’ Meeting report.

### 2. Epidemiology, pathophysiology, and topical treatment of glaucoma

The glaucomas are a diverse group of intraocular pressure (IOP)-sensitive, progressive optic neuropathies that have in common a characteristic pattern of retinal ganglion cell (RGC) loss (‘glaucomatous optic neuropathy’).

\* Corresponding author. Tear Film & Ocular Surface Society, USA.

E-mail address: [david@tearfilm.org](mailto:david@tearfilm.org) (D.A. Sullivan).

<https://doi.org/10.1016/j.jtos.2023.05.012>

Received 10 February 2023; Received in revised form 24 May 2023; Accepted 29 May 2023

Available online 9 June 2023

1542-0124/© 2023 Elsevier Inc. All rights reserved.

Glaucoma is the leading cause of irreversible vision loss worldwide and its prevalence is increasing due to its age-related nature [1]. Glaucoma affects about 4% of the population over 60 years and as many as 10% of the population over 80 years [1,6], including about 4 million people with blindness due to glaucoma [7]. Even mild forms of the disease are linked to measurable loss of mobility and functional independence, especially in the elderly: reading speeds, rates of falls, time out of the house, physical activity and cessation of driving are all worse with increasing visual field damage [8–13].

The main phenotypes are characterised by anterior chamber angle anatomy ('open' or 'closed'), the former (primary open-angle glaucoma; [POAG]) being more common but the latter (angle-closure glaucoma) accounts for half of all blindness. Seventy-five million cases of POAG alone are predicted by 2025, with the highest rates in Africa (prevalence 4.5% over 40 years) and Latin America (3.7% over 40) [14]. Glaucoma is predicted to affect over 112 million individuals by 2040 [15]. Largely because early forms of the disease may be unrecognised by patients, up to 50% of glaucoma in established market economies is undiagnosed (rising to over 90% in areas with less developed healthcare systems) [16].

Glaucoma treatment is chronic and only decreases the rate of disease progression, but is not curative and therefore places a considerable burden on secondary care services. With aging populations worldwide the numbers of individuals with glaucoma are predicted to rise significantly (e.g., by 30% in the UK in the next 15 years), while at the same time the availability of often more costly, complex treatments increase the cost of care [17].

Glaucoma is a highly heritable disease compared to other common conditions (70% versus, for example, 50% for diabetes) [18]. Individual 'risk factors' for developing glaucomatous optic neuropathy may be considered at the patient, eye, or tissue level and include age, race, myopia, vascular characteristics (such as response to nitric oxide, blood pressure medications) [19], inflammation [20,21] and mitochondrial dysfunction [22,23]. These interact, for example the impact of age is much greater in some races, POAG prevalence increases to over 20% in the ninth decade for Latino and African populations against 5–10% in white Europeans, while the increased risk from myopia is greater at lower IOP and greater age [7,24,25].

The primary site of damage is at the optic nerve head where profound mechanical stresses on the RGC axons as they leave the eye create significant energy demands for the cells [26]. Nonetheless, IOP reduction remains a powerful and proven means to prolong RGC survival, decrease the rate of glaucoma progression, and prevent blindness if treatment is initiated in time [25,27].

The most common treatment for lowering IOP is the use of eye drops [27]. Unfortunately, anti-glaucomatous eye drops have significant adverse effects, which when combined with the silent nature of glaucoma leads to a high risk of low adherence if patients do not understand their disease and the importance of treatment [28]. The introduction of generic eye drops has led to concerns about differences in both efficacy and side effects of these versus the branded eye drops. Moreover, the different expression of generic eye drops in terms of bottle design and hardness of the bottle increases the risk of confusion for patients and thus reduced adherence.

There are very few regulations to fulfill when introducing a generic eye drop and thus new generics enter the market on a regular basis. Recent findings suggest major variations between generic drugs, both in terms of physical and chemical properties [29–31], and also in terms of adverse effects and efficacy [32–34]. The impact of such variations can become detrimental for patient adherence and in the end lead to visual disability that could have been prevented. There is a need for more research that can provide an evidence-based basis for counseling patients and colleagues in choosing eye drops [35].

### 3. Impact of topical glaucoma medications on the ocular surface and adnexa

#### 3.1. Prevalence of, and risk factors for, ocular surface disease in glaucoma patients

Ocular surface disease (OSD) in glaucoma patients is common and frequently unrecognized and untreated. The prevalence of OSD in glaucoma patients is between 48 and 59% when based on symptoms, and between 22 and 78% when based on signs [36–38].

Jaenen et al. [39] performed a multicenter, cross-sectional epidemiological survey in four European countries including 9658 nonconsecutive glaucoma patients using preserved (74%) or preservative-free (12%)  $\beta$ -blocking eye drops; 52% of their study population were female with a mean age of 65 years. Each recorded symptom was significantly more frequent in the preservative group compared to the preservative-free group ( $p < 0.0001$ ). The symptom "Dry Eye Sensation," for example, was present in 34.9% of patients with preserved glaucoma medication versus 16% in patients with preservative-free medication [39]. Each recorded sign (e.g., eczema, anterior/posterior blepharitis, conjunctival hyperemia, follicles, and staining) was also significantly more frequent in the preservative group compared to the preservative-free. The clinical sign "corneal staining" was present in 25.6% of patients with preserved anti-glaucoma medications compared to 8.9% with preservative-free drops [39].

Erb et al. [40] included 20,506 glaucoma patients from 900 centers in Germany in a register. Epidemiological data, glaucoma medications, concomitant disease, dry eye disease (DED) and ocular symptoms were analyzed using a questionnaire, and the form of glaucoma was noted. The prevalence of DED in glaucoma was 52.6% (men 45.7%; women 56.9%) and increased with age (31.3% below 40 years; 61.6% over 90 years) DED was more common in PEX glaucoma (60.9%), followed by POAG (52%), and pigment dispersion glaucoma (45.2%). The duration of glaucoma was relevant with 47.3% of glaucoma between 1 and <2 years, and 55.2% between 10 and <15 years suffering from DED. The prevalence of DED increased with the number of eye drops used (1 eye drop 50.9%, 5 eye drops 66.7%) [40].

Leung et al. [5] analyzed 101 patients with POAG or ocular hypertension under antiglaucoma medication in a cross-sectional study: 59% of patients suffered from DED symptoms (27% severe), 61% had a reduced Schirmer test (35% severe), 22% showed ocular surface staining and 78% demonstrated a reduced TFBUT (65% severe). Each additional BAK-containing eye drop was associated with an approximately 2 times higher odds of showing abnormal lissamine green staining [5].

In a prospective observational study, Fechtner et al. [41] evaluated 630 patients from 10 centers in the US with POAG or ocular hypertension under topical glaucoma treatment. Symptoms of DED as analyzed by OSDI questionnaire were seen in 21.3% (mild), 13.3% (moderate), and 13.8% (severe). No influence of age, sex, and/or ethnicity could be detected. Also in this study, the number of glaucoma medication was relevant for the occurrence of DED symptoms. Moreover, pre-existing DED was significantly associated with DED symptoms under glaucoma treatment ( $p = 0.004$ ) [41].

Several risk factors for the development of DED symptoms and signs were observed in the epidemiological studies presented above including female sex, higher age, preexisting DED, glaucoma type, duration of glaucoma, number of glaucoma medications, and preservatives, especially benzalkonium chloride [5,39–41]. In addition, the frequency of instillation has been recognized as an additional risk factor [42].

An interesting question remains whether glaucoma itself can induce ocular surface disease. In a study by Kuppens et al. [43], the basal tear turnover was significantly reduced in untreated POAG compared to healthy controls and patients with ocular hypertension ( $p = 0.001$ ). The authors speculated that DED complaints may originate from decreased basal tear turnover as a result of glaucoma drug therapy, as well as from primary open-angle glaucoma itself [43].

In addition, glaucoma surgery has been discussed as a risk factor for OSD. Eyes with functioning blebs after trabeculectomy had higher rose Bengal and fluorescein staining ( $p < 0.001$ ) and lower TF BUT compared to controls ( $p < 0.05$ ). The staining correlated poorly with height and extent of the bleb [44]. Also, Ji et al. [45] observed significantly higher corneal staining scores ( $p = 0.012$ ) and lower TF BUT ( $p = 0.043$ ) in bleb patients with significantly higher prevalence of DED ( $p = 0.018$ ). In this study, DED correlated with bleb height [45].

The adverse effects of topical glaucoma medications are not limited to the generation or exacerbation of DED. For example, up to 25.7% of patients develop allergic reactions to brimonidine, including dermatitis conjunctivitis and follicular conjunctivitis [46]. This allergic response to brimonidine does not happen immediately, but rather may occur months and sometimes years after initiating treatment [47,48] and is associated with a loss of IOP control [47]. Timolol may also induce allergic contact dermatitis [49,50], and various anti-glaucoma eye drops have been linked to the impairment of corneal wound healing [51] and dysfunction of corneal limbal stem cells [51]. In addition, topical glaucoma treatment may also cause pseudopemphigoid [52] and mucous membrane pemphigoid, which could lead to blindness [53].

It should be recognized that in general, glaucoma surgery and the discontinuation of glaucoma medications have a positive effect on the ocular surface. Tong et al. [54] for example demonstrated a long-term beneficial effect of trabeculectomy on the ocular surface with a reduced expression of conjunctival inflammatory genes and immune-related genes postoperatively [54].

### 3.2. Adverse effects of active ingredients in glaucoma medications on the ocular surface and adnexa

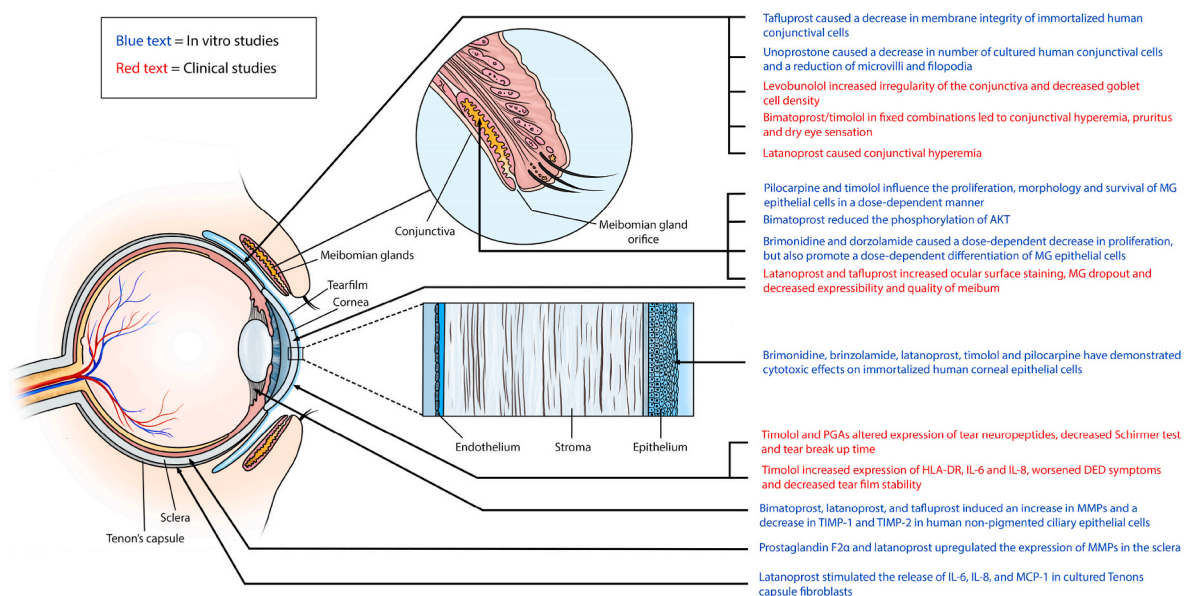
The prevalence of DED ranges from 5 to 50% [2]. Among patients being treated for glaucoma with IOP-lowering eye drops, the prevalence is reported to increase to as much as 45–60% [4,5]. Although the use of preservatives has well-documented negative effects on the ocular surface (see below), the active ingredients may have deleterious effects as well (Fig. 1).

Prostaglandin F<sub>2α</sub> and latanoprost exposure upregulates the expression of matrix metalloproteinases (MMPs) in organ cultured human sclera [55]. Bimatoprost, latanoprost, and tafluprost induce an increase in MMPs, as well as a decrease in tissue inhibitors of

metalloproteinase (TIMP)-1 and TIMP-2 in human non-pigmented ciliary epithelial cells [56]. Tafluprost causes a decrease in membrane integrity of immortalized human conjunctival cells [57]. Brimonidine, brinzolamide, latanoprost, timolol and pilocarpine have demonstrated cytotoxic effects on immortalized human corneal epithelial cells [58]. Release of pro-inflammatory mediators was reported following exposure of human Tenon's capsule fibroblasts to latanoprost, but not to timolol and pilocarpine [59]. Unoprostone caused a decrease in number of cultured human conjunctival cells and a reduction of microvilli and filopodia [60]. Latanoprost stimulated release of lactate dehydrogenase in aqueous humor, goblet cell damage, macrophage infiltration of eyelids and conjunctival redness in rabbits [61]. Bimatoprost also induced eyelid infiltration of macrophages [61].

Clinically, latanoprost caused conjunctival hyperemia [62]; bimatoprost/timolol in fixed combinations led to conjunctival hyperemia, pruritus and DED sensation [63]; timolol and prostaglandin analogues (PGA) altered tear neuropeptides expression [64]; preservative-free timolol increased expression of human leukocyte antigen (HLA)-DR, interleukin (IL)-6 and IL-8, although less than preserved formulations [65], worsened DED symptoms and decreased tear film stability [66]. In contrast, another study found no alteration in HLA-DR, intercellular adhesion molecule-1 or mucin expression following exposure to timolol [67]. Levobunolol increased irregularity of the conjunctiva and decreased goblet cell density [68]. Two prospective, randomized studies found no detrimental clinical effects of tafluprost [69,70], however, one did observe an increase in goblet cell density [69]. Several switch-studies have demonstrated improved signs and symptoms upon changing from preserved to preservative-free PGA [71–75] or from preserved to preservative-free  $\beta$ -blockers [76,77]. Moreover, several larger multicenter studies reported improved symptoms and signs when changing to an unpreserved alternative drug [39,42,78,79].

Studies of immortalized human meibomian gland (MG) epithelial cells found that pilocarpine and timolol influence their proliferation, morphology, and survival in a dose-dependent manner [80]; brimonidine and dorzolamide cause a dose-dependent decrease in proliferation, but also promote a dose-dependent differentiation of these cells [81,82]; and bimatoprost reduced the phosphorylation of phosphoinositide 3-kinase (PI3-kinase)-protein kinase B, an effect that would attenuate MG epithelial cell survival [83]. Compared to healthy controls, patients treated with latanoprost and tafluprost presented increased ocular



**Fig. 1.** Effects of unpreserved anti-glaucoma eye drops on the eye's anterior segment. Active compounds were used in the studies *in vitro*, whereas commercial formulations were used in the clinical studies. The references are cited in Section 3.2.



surface staining, MG dropout and a decreased expressibility and quality of meibum [84]. A later prospective study examining the same PGA found no evidence of increased MG dropout compared to baseline during 12-month follow-up [85]. Moreover, tafluprost and timolol did not cause any discernible clinical or microscopic changes measured with *in vivo* confocal microscopy (IVCM) compared to healthy controls [86]. However, patients treated with bimatoprost/timolol fixed combination demonstrated worse scores concerning signs and symptoms of DED, goblet cell density and MG parameters measured with IVCM compared to healthy controls [87].

### 3.3. Adverse effects of active ingredients in glaucoma medications on the nasolacrimal duct and periorbital area

Topical instillation of anti-glaucoma medication to the ocular surface may have significant periocular impact. The fornix capacity for storage is around 30  $\mu\text{l}$ , with a typical drop volume of 50  $\mu\text{l}$ , around 20  $\mu\text{l}$  will run into the lacrimal drainage system or over the lid margin [88]. Peri-orbital changes mostly associated with prostaglandin analogues, include lipodystrophy and eyelid malposition with resultant functional and aesthetic impact [89,90]. Ptosis, upper and lower eyelid retraction, increased horizontal eyelid tension, trichiasis, ectropion and entropion have been described [91–93]. Aesthetic changes may be asymmetrical with unilateral eye drop instillation. Deepening of the upper eyelid sulcus was first described in 2004 with bimatoprost [94]. It has since been described with other PGA [95–97], age and duration of PGA use being positively and independently associated [98]. Prostaglandin-associated periorbitopathy (Fig. 2) also includes loss of the inferior orbital fat pads, enophthalmos, eyelid pigmentation and eyelash changes [99–101]. The reduction of pre-aponeurotic fat and orbital fat volume is thought to be due to apoptosis of orbital fibroblasts and remodeling of the extracellular matrix [102].

Exposure to PGA *in vitro* has been shown to suppress adipogenesis in differentiated adipocytes [103] in a dose dependent manner. These findings have been confirmed on MR imaging [104] and may play a therapeutic role in adipogenic orbital diseases, such as thyroid associated orbitopathy [105,106]. PGA prolongation of the anagen phase in resting hair follicles, results in hypertrichosis. Eyelash growth has been seen with all PGA at varying frequencies [107]. Hypertrichosis has also been described in a lower eyelid skin graft and cheek post basal cell carcinoma excision [108]. PGA induced eyelid pigmentation by tyrosinase transcription induction in melanocytes has been described [109, 110], and cases of melanoma have been reported [111,112]. The general

prevalence of nasolacrimal duct and sac obstruction is around 9% in asymptomatic patients [113]. Observation of acquired external punctal stenosis [114] and canalicular narrowing [115] led to further study of lacrimal drainage system obstruction by anti-glaucoma eye drops. An increased incidence of obstruction is seen in patients on such drops [116], with the upper canaliculus more likely to be affected than the lower [117], presumably due to the closer proximity to the conjunctiva and fornix, and more likely with combination therapy. Timolol induced lacrimal drainage system obstruction has been widely reported [118]. A combination of chronic inflammation causing cicatricial changes, and autonomic nervous system effects on the width of the nasolacrimal drainage system are thought to play a role [118].

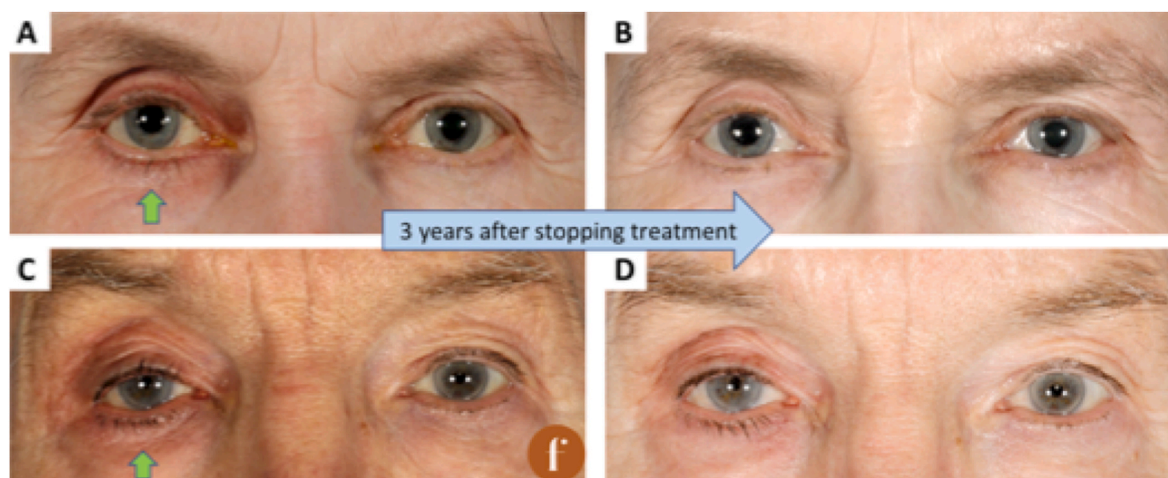
### 3.4. Adverse effects of BAK preservatives in glaucoma medications

Long-term use of eye drops is a common cause of significant changes in the ocular surface, as shown by both basic science and clinical research [1,2]. Chronic low-grade inflammation from these drops is particularly common in glaucoma patients, whose life-long use can result in a variety of clinical manifestations. Decades-long use of these medications may cause and/or exacerbate ocular surface conditions such as chronic allergy, meibomian gland dysfunction and DED, thus affecting compliance, surgical results, and quality of life [119,120].

Benzalkonium chloride (BAK) is the most common eye drop preservative, and there is a correlation between the number of BAK-preserved drops used concurrently and the development of adverse ocular surface signs and symptoms [5,42]. This association is supported by the significant improvement in signs and symptoms upon discontinuing the preserved drops and switching to preservative-free drops [42,79].

Due to its surfactant properties, BAK has an adverse effect on the tear film. BAK promotes pro-inflammatory effects and epithelial and goblet cell toxicity and may increase tear osmolarity [119,121]. Thus, BAK may destabilize the tear film and cause and/or exacerbate DED [20].

*In vitro* studies have shown that BAK is toxic to conjunctival cells exposed to osmotic stress [122]. Further, it is well documented that BAK significantly decreases cellular viability in a concentration-dependent manner, through oxidative stress and increased apoptosis. This proapoptotic effect of BAK begins at a toxicity threshold of approximately 0.005%, below the concentration typical of most eye drops [119]. In corneal cell cultures BAK causes large changes in cell membrane lipids, increasing the proportions of certain lipids such as ceramides, implicated in the inflammatory response and cellular death [123]. Moreover, BAK concentrations that are hundreds-fold below limits set for human



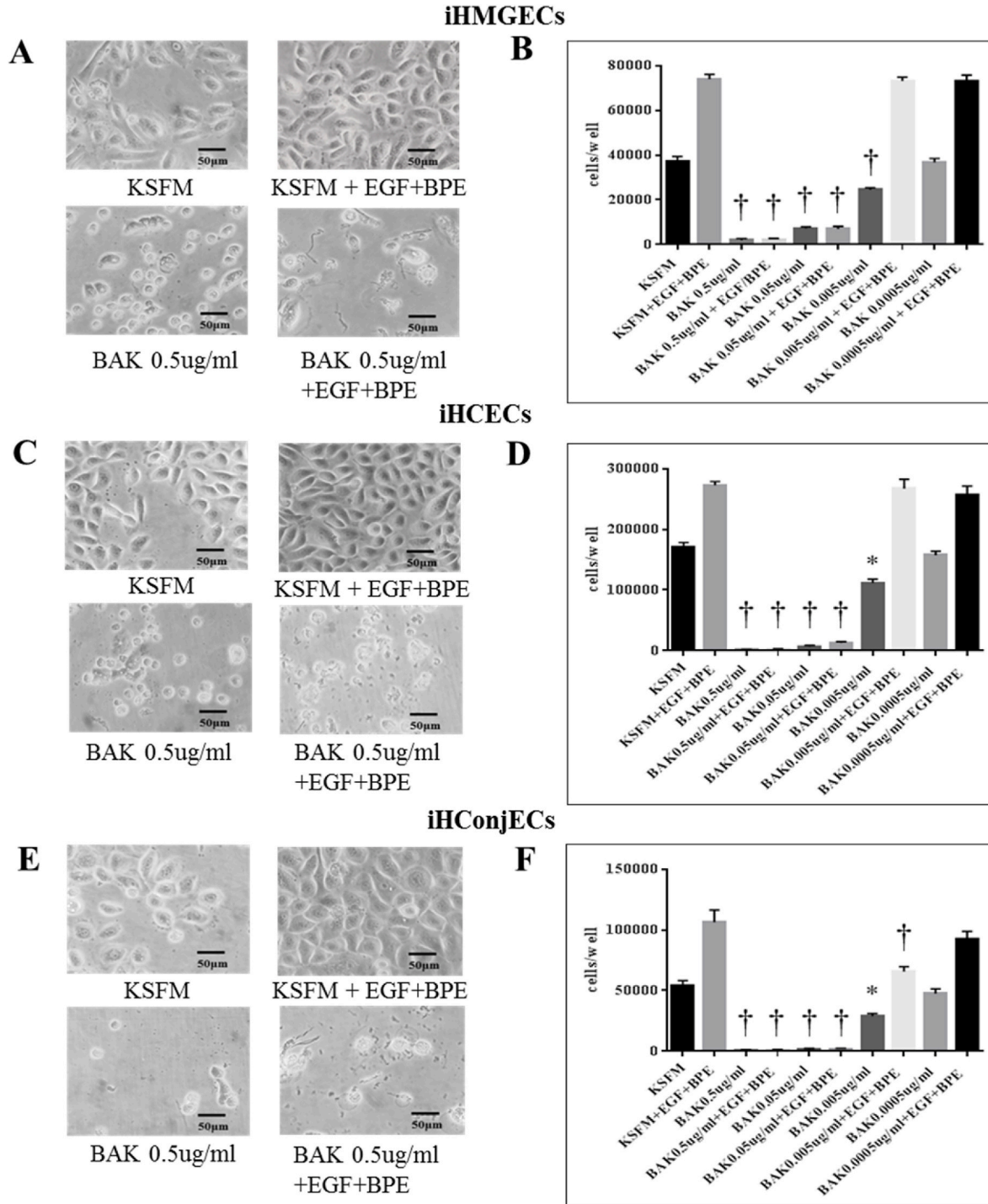
**Fig. 2.** Two patients (A & C) treated with bimatoprost 0.03% for glaucoma to their right eyes only. Treatment of the right eyes demonstrates hollowing of the superior sulcus, but less dermatochalasis, skin hyperemia, ptosis and enophthalmos compared to the untreated left eyes. The right eyes also have a more pigmented and darker lid margin, as well as more prominent lashes. Even three years after cessation of treatment (B & D respectively), the fat atrophy persists. (Images courtesy of Dr. Rachna Murthy).

commercial products kill all human corneal, conjunctival and meibomian gland epithelial cells *in vitro* within 18 h [124] (Fig. 3).

Studies *in vivo* have demonstrated that BAK is toxic for trigeminal nerve endings [125], findings that are consistent with those of an investigation examining the effects of preserved vs preservative-free glaucoma drops on corneal nerves by IVCN [126]. This study also showed decreased corneal sensitivity on esthesiometry in the study

groups on preserved drops compared to the control group or groups on preservative-free prostaglandins or  $\beta$ -blockers [126]. The relative comfort of patients on BAK-containing drops despite their ocular surface disease might be explained by this neurotoxicity.

Research has also shown direct inflammatory effects of BAK on the ocular surface by inducing the release of inflammatory cytokines and/or increasing the expression of chemokine and cytokine receptors [127,



**Fig. 3.** Impact of BAK on the survival and proliferation of immortalized human meibomian gland (iHMGECS), cornea (iHCECs) and conjunctival (iHConjECs) epithelial cells. Cells were exposed to vehicle or BAK in the presence or absence of growth supplements (epidermal growth factor and bovine pituitary extract) for 5 days before cell counting. BAK caused toxic morphological changes in iHMGECS, iHCECs and iHConjECs. All images are 200 × magnification. Scale bar is 50 μm (A, C, E). Results are shown as mean ± SE. \*p < 0.05, †p < 0.001 (B, D, F). Significance signs represent comparisons between basal conditions with or without BAK, or growth factor-containing cultures with or without BAK. This figure is reproduced from Chen X, Sullivan DA, Sullivan AG, Kam WR, Liu Y. Toxicity of cosmetic preservatives on human ocular surface and adnexal cells. *Exp Eye Res.* 2018; 170:188–197.

[128]. There are high levels of the inflammatory marker HLA-DR in the ocular surface after exposure to preserved eye drops [67]. Other markers of inflammation, such as ICAM-1, interleukins IL-6, IL-8, and IL-10, CCR4 and CCR5, also appear to be overexpressed in glaucomatous eyes, especially so with multiple medications and preserved eye drops [129]. BAK may also accumulate in deeper ocular tissues [130]. Increased anterior chamber flare has been reported with BAK-preserved glaucoma drops, likely due to a break-down in the blood-aqueous barrier [131].

### 3.5. Adverse effects of non-BAK preservatives in glaucoma medications

The primary reason for use of preservatives is that microbial contamination in eye drops is a significant risk factor for sight-threatening complications, such as infectious keratitis [132]. The contents of multi-dose ophthalmic containers, used twice daily or more frequently, often undergo bacterial contamination within one to two weeks, and patients may use an individual bottle for months [132]. Consequently, preservatives are added to ophthalmic preparations to reduce or eliminate microbial growth [132]. Furthermore, ophthalmic medications stored in multiple-dose containers are required by the US Pharmacopoeia and the European Pharmacopoeia to contain a preservative [133].

A secondary reason was that detergent preservatives, such as BAK, were needed to permit prodrugs (e.g., PGA) to pass through the cornea and become activated for the treatment of glaucoma [119]. However, this facilitation has been shown not to be necessary [62].

Because of the well-described adverse effects with BAK, as explained above, other preservatives have been developed. These include cell membrane lysing detergents (e.g., polyquaternium-1), oxidizing preservatives (e.g., sodium perborate), ionic-buffered preservatives (e.g., borate, sorbitol, propylene glycol and zinc), and chelating agents (e.g., ethylenediaminetetraacetic acid) [134].

However, the properties of these preservatives are due to certain chemical groups that may be harmful to living cells and may elicit adverse ocular effects [135–137]. Preservative free systems, in the form of unit dose packages, may be a viable alternative to traditional multi-dose bottles [9]. Ophthalmic preparations without preservatives are especially important for individuals requiring long-term treatment who cannot tolerate drops containing preservatives [138]. Examples of such individuals are glaucoma patients, who may need lifelong treatment [139].

### 3.6. Adverse effects of antimetabolite treatments following glaucoma filtration surgery

Reduction of IOP is the sole proven means to prolong optic nerve survival and is thus the mainstay of glaucoma treatment, whether by laser, medication or surgery. While multiple techniques exist, the traditional trabeculectomy remains a widely used, reliable and powerful procedure [140,141]. Its success depends upon control of conjunctival and sub-tenon wound healing, which otherwise leads to scarring and surgical failure. Topical and depot corticosteroids are universally used post-operatively to suppress inflammation, while the toxic anti-metabolites 5-Fluorouracil (5FU) and Mitomycin C (MMC) are very widely used to control tenons fibroblast proliferation [142–148]. More recent drugs such as anti-VEGF antibody bevacizumab, are in widespread use but have less evidence on either effectiveness or harms [149, 150].

5-FU reversibly inhibits thymidylate synthetase to block DNA synthesis with inhibitory effects from cell cycle arrest [151]. Previously used per-operatively it is now chiefly used post-op via sub-conjunctival injections, often multiple, with the risk of reflux onto the ocular surface [151].

MMC is a Streptomyces-derived alkylating agent that crosslinks DNA to inhibit DNA, RNA and protein synthesis, has a cytotoxic effect on

fibroblasts and is apoptotic at high doses [152]. It is applied by either pre-op sub-conjunctival injection or per-op on MMC-soaked sponges. High doses or misapplied drug can lead to poor wound healing, excessive drainage, and even scleral necrosis [152].

Effects on the ocular surface can be via direct toxic effects on corneal and conjunctival epithelial cells, damage to corneal limbal stem cells [153,154], and meibomian glands [155] or indirect via disruptions to healthy ocular surface homeostasis from conjunctival goblet cell loss and large avascular drainage blebs interfering with adequate surface wetting. Reduced conjunctival integrity also leads to greater risks of devastating intraocular infection.

Glaucoma patients are already a very high-risk group with high rates of ocular surface disease due to age, comorbidity, and long-term glaucoma medication use with exposure to toxic preservatives. Further exposure to anti-metabolites can put them at still greater risk of symptomatic OSD.

### 3.7. Treatment outcomes: tolerability, compliance, and quality of life

The goal of glaucoma care is to promote patient well-being and quality of life within a sustainable health care system [156]. Quality of life is influenced by severity of visual dysfunction, the impact on ability to perform vision-related tasks of daily living, the psychological impact of disease, and the costs and side effects of treatment [156]. These factors are closely interlinked, for example, a poorly tolerated topical medication may lead to short-term reduction in quality of life due to ocular surface or periocular side effects, but also lead to poor adherence, with resulting poor disease control, faster glaucoma progression, and long-term reduction in quality of life due to worsening visual field loss.

The treatment of glaucoma tends to focus on IOP reduction. However, IOP is a surrogate of which patients are not directly aware [157]. Glaucoma care should take a holistic approach and consider treatment from the patient's perspective [158].

In its early stages glaucoma is typically asymptomatic and for many patients the main symptoms experienced are related to the adverse effects of topical medications. Though surveys have indicated that approximately 80% of glaucoma patients are satisfied with their topical ocular anti-hypertensives, these have included a preponderance of patients on monotherapy and a large proportion ( $\geq 25\%$ ) were also using tear substitutes [38,159]. Also, a reported limitation in one of these surveys [38] was that patients were asked about any dissatisfaction with their treatments by their own ophthalmologists, which may have introduced a bias, given that many patients may have belittled their symptoms. It should be noted that the prevalence of OSD in patients with glaucoma is higher than in similarly aged controls [160,161].

Tolerability is intricately linked to adherence, which is defined by the World Health Organisation, as the extent to which a person's behaviour corresponds with agreed recommendations from a healthcare provider [162]. A patient with poor tolerance to a medication is more likely to be poorly adherent, though paradoxically poorly adherent patients may report higher satisfaction with treatment due to less adverse effects. Poor adherence to glaucoma medications is associated with a higher risk of progressive visual field loss and adherence also decreases with more complex dosing regimens. Identifying poor adherence is challenging particularly as there is poor correlation between self-reported adherence and other measures such as electronic dose monitoring and pharmacy refill information. Nevertheless, a recent study identified the question "over the past month what percentage of your eye drops do you think you took correctly?" as having good ability to predict adherence measured with electronic monitoring, with the optimal cut off for poor adherence as  $\leq 85\%$  of drops [163].

An important tool for considering treatments from the patient perspective are patient reported outcome measures (PROMs). Though PROMs may be insensitive for detecting short-term changes in severity of glaucoma, they are an important tool for informing treatment safety and tolerability [164]. PROMs may focus on general health (e.g.,



EuroQoL-5D) or be vision (e.g., NEI-VFQ-25) or disease specific (e.g., GQL-15, GQL-9, GSS or GUI). Some of the glaucoma specific quality of life questionnaires include questions related to ocular pain or discomfort (e.g., GSS and GUI), whereas some do not (e.g., GQL-15 and GQL-9) [165]. In the GSS, for example, 6 of 10 items are related to ocular pain or discomfort. Choosing treatments that are better tolerated is therefore likely to lead to improvement in quality-of-life scores obtained using some but not all glaucoma PROM questionnaires. PROMs are also used to diagnose and assess severity of ocular surface disease (e.g., OSDI and DEQ-5) [166,167]. Caution should be exercised if considering using the OSDI in patients with glaucoma as it contains several questions related to visual function that may be affected by glaucomatous visual field loss, rather than OSD [168]. Neither the OSDI nor DEQ-5 have been validated for use in glaucoma, but the DEQ-5 is likely more specific for OSD as it lacks questions on visual function.

Randomised control trials may fail to fully capture long-term issues with tolerability as they typically of short duration, evaluate only monotherapy and exclude patients with DED or blepharitis. There is also variation in how treatment side effects are measured complicating comparisons between studies. Recently, a Delphi approach was used to establish consensus on outcomes and methods to assess adverse effects of anti-glaucomatous eye drops in clinical trials [169]. The eight outcomes ranked most important (in order) were 1) ocular surface, dryness, epithelial damage, 2) patient-reported local adverse events, 3) periocular surroundings and eyelids, 4) quality of life questionnaires, 5) hyperaemia, 6) visual acuity, 7) tear film, and 8) anterior chamber inflammation.

#### 4. Impact of pre-existing ocular surface disease on glaucoma treatment

##### 4.1. Management of ocular surface disease in glaucoma patients

Many observational studies based on real world evaluations consistently showed a large proportion of patients suffering from symptoms and signs of ocular surface disease [20,42,170]. Globally, approximately 50% of glaucoma patients suffer from DED symptoms and signs, of whom 20–30% are considered with severe conditions, which is much more than expected according to the prevalence of DED in the same age population. In one large epidemiological survey conducted in 4,107 glaucoma patients [42], frequency of signs and symptoms increased with the number of preserved eye drops used and was significantly lower for all criteria in a group of patients treated with unpreserved beta blockers. Another study showed a clear relationship between the number of medications, irrespective of their family, which may suggest a common compound leading to such side effects, possibly the preservative, the only component common to all eye drops [170]. Interestingly, a more recent survey showed that almost 38% of glaucoma patients were using tear substitutes, more than half of them being preserved, which illustrates the lack of knowledge of the iatrogenic causes of DED in glaucoma, the usual strategy for treating DED consisting of adding treatments to alleviate symptoms rather than considering the cause, and eventually the illogical use of preservative-containing eye drops for treating iatrogenic DED [171].

When DED has progressively developed over time during anti-glaucoma treatments, switching to preservative-free medications should be the first choice, rather than adding tear substitutes or anti-inflammatory agents. This would emphasize a “subtractive strategy”, which is likely more effective because it targets the origin of the disease or one of its cofactors, rather than an “additive strategy,” consisting of adding medications to counteract the iatrogenic effects of other drugs [20,120]. Data from studies where such switches have taken place suggest reversible drug-induced ocular surface changes, which may improve when the causative or aggravating factor is removed [79] or even decreased [42]. In those studies, reversibility of inflammatory lesions can be obtained rapidly, as also shown with dendritic cells level

returning to normal in less than one month [172]. In an Australian survey in 375 patients, switching to unpreserved antiglaucoma eye drops showed a decreased use by patients of tear substitutes, improvement in a quality-of-life questionnaire, decreased number of patients with abnormal tear instability with no negative effect on intraocular pressure control [173].

However, removal of an aggravating factor may not be sufficient for treating DED associated with glaucoma. Specific DED therapy may therefore be addressed, such as preservative-free tear substitutes, or topical cyclosporine, in order to counteract the inflammatory reactions often associated with dry eye, avoiding steroids as much as possible in glaucoma patients.

Not all patients are sensitive to preservatives and not all adverse effects observed with antiglaucoma medications are induced by preservatives. Three factors must in fact be considered: the active compound, the preservative, and the patient’s ocular surface. Patients with preexisting ocular surface disease when glaucoma treatment is initiated as well as those developing DED or ocular irritation during glaucoma therapy should receive particular attention. Simple clinical tests may help the clinician detect ocular surface disease, such as assessment of symptoms of irritation or dryness, eyelid margin redness, positive corneal and conjunctival vital dye staining, and rapid tear film break-up time.

In such cases, quality of life, adherence, surgical outcome, and overall glaucoma care may be adversely affected. It is therefore advisable to consider treatment alternatives, such as removing the preservative when possible or at least decreasing the number of preserved eye drops by using fixed combinations or medications with preservatives other than BAK, treating the ocular surface with unpreserved tear substitutes, and considering laser trabeculoplasty or surgery to decrease the number of eye drops.

Alternatively low toxicity preservatives have been developed and showed little if no effects to the ocular surface [120,128,174]. They can be proposed as a way to subtract or reduce the most toxic compounds. In case of DED, they can provide safer options than those obtained with BAK.

Whenever possible, the subtraction strategy is thus always preferable when considering iatrogenic effects [20,120]. The first step is identification of the role a drug or compound, which may be very difficult when adverse effects occur late after introducing the treatment, when several drugs and components are used, when the ocular surface is concomitantly impaired or when the treatment cannot be interrupted without endangering the eye condition. The use of eye drops to alleviate symptoms of DED may be necessary but adding preserved eye drops to a DED induced by other eye drops, and likely the preservative, is at least ineffective and at worse a cause of further aggravation.

To assist eye care practitioners in the management of OSD in glaucoma patients, an evidence-based, stepwise treatment approach is presented in Table 1.

Rationales for the diagnostic assessments and therapeutic considerations in this Table are provided in the text. The reasons for considering management of periocular (e.g., adverse eye cosmetics) [175] and environmental (e.g., low humidity, allergens, etc.) [176] factors have recently been published in detail.

##### 4.2. Management of glaucoma in ocular surface disease patients

As noted above, the prevalence of both glaucoma and OSD increase with aging, both often coexisting, and may be present within a spectrum ranging from mild to severe stage [1,2]. This association makes treatment more demanding from a clinician’s and patient’s perspective. The goal of glaucoma care is to promote patients’ well-being by preserving their visual function and quality of life at a sustainable cost [156]. Costs include inconveniences to the individuals due to side effects and costs of treatment, diagnostic procedures, and examinations. Loss of visual function affects quality of life, which is considerably reduced in

**Table 1**  
Management of ocular surface disease (OSD) in glaucoma.

Step 1: Evaluate patients for OSD prior to treatment initiation
<ul style="list-style-type: none"> <li>Assess risk factors: Aging, systemic autoimmune diseases (e.g. Sjögren syndrome), meibomian gland dysfunction (MGD), post-LASIK/refractive surgery, topical (e.g., anti-histamines) and systemic (e.g., anti-androgens) medications, atopy, allergic conjunctivitis, contact dermatitis, rosacea, overuse of artificial tears, etc.</li> <li>Evaluate symptoms of OSD: dryness, grittiness, pruritus, etc.</li> <li>Examine signs of OSD: Eyelid/conjunctival redness, swelling, crusts, debris, collarettes, corneal and/or conjunctival vital dye staining, short tear film breakup time (BUT; &lt;5 s), etc.</li> </ul> <p><i>In case of OSD or significant risk factors for OSD, consider preservative-free eye drops or selective laser trabeculoplasty (SLT) as a first-line therapy</i></p>
Step 2: Re-evaluate regularly patients for OSD during treatment course
<ul style="list-style-type: none"> <li>Assess symptoms of OSD, increased need for tear substitutes, eyelid/conjunctival redness/swelling, corneal and/or conjunctival staining, short BUT <i>Note that the occurrence of OSD increases with duration of treatment, multiple eye drops and patient aging</i></li> <li>Evaluate consequences of OSD on patient outcomes: adherence, acceptability, need for additional eye drops and treatments (tear substitutes, anti-allergic agents, lid hygiene, or other procedures addressing MGD), impact on quality of life and vision (blurred or unstable vision, photophobia, ocular fatigue)</li> </ul>
Step 3: In case of significant OSD interfering with glaucoma outcomes
<ul style="list-style-type: none"> <li>Identify mechanisms: allergy vs. dry eye, inflammation or irritation. In case of intolerance (e.g., pruritus, eczematous lesions of the eyelid) to different eye drops containing the same compound, consider an allergic mechanism</li> <li>Prioritize reduction/removal of the potential agents of intolerance/irritation (prescribe preservative-free eye drops when available) or allergy (look in particular for reactions occurring after introduction of brimonidine, timolol, etc.)</li> <li>Consider managing periorcular (e.g., adverse eye cosmetics) and environmental (e.g., low humidity, allergens, etc.) factors</li> <li>Consider switching to other compounds when available and reevaluate OSD after removal/switch</li> <li>Consider fixed combinations, SLT or surgery for removing/reducing anti-glaucoma eye drops</li> <li>Consider treating OSD as adjunctive treatment: preservative-free tear substitutes, anti-allergic agents, lid hygiene and/or mechanical procedures, cyclosporine or other anti-inflammatory agents, oral tetracycline derivatives or azithromycin, etc.</li> <li>Avoid corticosteroids that may increase intraocular pressure (IOP)</li> </ul>
Step 4: If glaucoma surgery is required, either for eye drop intolerance or insufficient IOP control
<ul style="list-style-type: none"> <li>Consider removing/reducing eye drops to minimize all pro-inflammatory agents for three to four weeks, and consider prescribing oral acetazolamide to control IOP if elevated and/or in severe glaucoma</li> <li>Consider prescribing anti-inflammatory eye drops before surgery</li> <li>Consider minimally invasive glaucoma surgeries in case of mild glaucoma</li> <li>Continue to evaluate OSD regularly after glaucoma surgery, especially in case of filtration techniques and filtering bleb formation</li> </ul>

advanced glaucoma [177]. Furthermore, patients often suffer from fear, anxiety and depression associated with the diagnosis of blinding disease [178]. IOP reduction is the only proven treatment to delay progression of glaucoma [25,179]. Usually for patients with advanced glaucoma lowering of IOP to low teens reduces progression of disease in majority of cases, but often several eye drops, laser or surgical treatment are required.

Treatment of glaucoma in patients with OSD is challenging, especially while managing glaucoma. The reason is that topical medications are usually first-line therapy, but these may further compromise ocular surface and worsen signs and symptoms of DED. To monitor and assess the rate of glaucoma progression, patients undergo frequent visual field testing. Unreliable visual fields make diagnosis and detection of glaucoma progression more difficult. Patients with increased DED symptom severity have greater deviations in gaze tracking and these tracking failures can occur due to blinking or poor corneal light reflex and reduce visual field reliability, thus delaying detection of disease progression [180].

In a newly diagnosed patient with glaucoma and co-existent ocular surface disease both need to be addressed and treated, depending on the severity of each disease and likelihood of visual function loss. The

clinician needs to consider patient-related disease specific factors, including glaucoma severity, one or two eye involvement, degree of IOP lowering required. In early to moderate open angle glaucoma or ocular hypertension with 20–30% lowering from baseline IOP, selective laser trabeculoplasty is a good option for first-line treatment, as it delays the need for topical treatment [181]. Treatment options should be clearly presented and patients' own awareness of their condition and preferences established, such that a decision about treatment is a joint one between clinician and patient [182]. When eye drops are preferred option, the least number of preservative-free eye drops, preferably PGA should be prescribed [156]. If initial monotherapy does not seem effective or the drug is not tolerated, treatment should be switched to another preservative-free monotherapy rather than adding a second drug. However, when drug effectively lowers IOP, but the target pressure is not reached or there is a progression of glaucoma, then adding a second preservative-free drug should be considered, preferably a fixed combination [156]. In most patients more than one drug is needed to lower IOP to target pressure.

Long-term topical anti-glaucomatous treatment especially with increasing number of preserved eye drops daily can exacerbate co-existing ocular surface disease or induce signs and symptoms of ocular surface disease and decrease patients' adherence [183,184]. Besides toxic-inflammatory effects of preservatives, side effects can be also due to active compound and excipients [185]. Signs and symptoms may not necessarily correlate, and patients may have minimal ocular surface staining but significant symptoms or may present with severe surface staining and blepharitis while being asymptomatic [186]. Switching from preserved to preservative-free medication and reducing the number of daily instillations may reduce signs and symptoms of DED [39, 173].

To reduce the burden of eye drops and improve adherence in patients with glaucoma, bimatoprost intracameral biodegradable implant has been approved by the FDA for single administration and there are ongoing studies evaluating long-term safety and efficacy. It releases bimatoprost for up to 6 months and its effect is equivalent to a single drop of bimatoprost 0.03% ophthalmic solution [187].

Glaucoma surgery in patients with ocular surface disease is recommended when target intraocular pressure has not been reached and the documented rate of progression is estimated to cause visual impairment during patients' lifetime. The primary goal is to achieve target IOP without additional medication. Trabeculectomy achieves the greatest IOP reduction but requires meticulous postoperative care and experience in filtering bleb management. Preoperative changes and subclinical inflammation of the ocular surface caused by topically preserved eye drops may reduce the success of filtration surgery [188]. Switching to preservative-free eye drops or stopping all eye drops and/or substituting for oral acetazolamide and adding preservative-free anti-inflammatory drops for several weeks may improve the outcome of surgery. Following successful trabeculectomy patients showed better ocular surface homeostasis (higher TBUT, lower grading of conjunctival hyperaemia and corneal staining) than fellow medically treated eyes [189]. In another study, clinical signs (redness and irritation) and the state of the conjunctiva improved throughout the 1-year follow-up while the levels of pro-inflammatory proteins decreased, and lipid transport-associated functions were increased [190]. However, formation of functioning high blebs with microcyst has been related to ocular surface instability and DED [45].

Non-bleb forming angle-based minimally invasive glaucoma surgery (MIGS) procedures are less interfering with the ocular surface and may be an option in patients with cataracts and mild to moderate glaucoma who do not require low target IOP. It has been reported that post-operative eye drop burden can be significantly reduced after stent placement, but larger well-designed studies with long-term follow-up are needed [191,192].



## 5. Therapeutic challenges

### 5.1. Bottleneck in bottle design

The independent scientific organization U.S. Pharmacopoeia (USP) has identified multiple causes of medication errors stemming from labeling and packaging designs [193]. With a look at three of these causes of error, the packaging designs may lead to medication errors by glaucoma patients. The errors can be either 1) Small size and poor readability of printed information, 2) Poor use or absence of colours to differentiate products, 3) Poorly designed or cluttered labels.

The mentioned shortcomings are due to policies resulting from the European legislation on medical information design, whose guidelines have no focus on the mutual interaction of design elements and their impact on individual user groups [194]. Good design can never be achieved by following a checklist, since all visual elements mutually interact. Understanding this dynamic is a prerequisite of functional design.

### 5.2. Point of view of glaucoma treatment from a patient with ocular surface disease

I am an 81-year-old individual who has suffered from glaucoma for the past twenty years. After my glaucoma diagnosis, the treatment was, and continues primarily to be, eye drops. I have tried many kinds of eye drops, but the result has never been comfortable. The drops have given me red eyes, eyelid eczema, an eye infection and foreign body sensations. Because I could not tolerate these eye drops, I was switched to preservative-free drugs.

I have undergone various glaucoma surgeries, but I still need eye drops, which continue to cause red and dry eyes, as well as dry, itchy, and drooping eyelids. I now read with my left eye exclusively.

My failing vision worries me. Further, the time courses for the various medications are difficult to track, and physically I feel different side effects from the eye drops in the form of muscle weakness and shortness of breath. I have increasing problems judging distances, and trip more often, because I have difficulties seeing ground irregularities, especially in the dark.

I hope that I will be able to stop using eye drops. I am very grateful for the glaucoma treatment I have received, and hope that I can keep the vision in my left eye.

## 6. Closing remarks

Glaucoma is most often treated with IOP-lowering eye drops, which in the vast majority of cases can prevent visual impairment and blindness if the drops are taken as prescribed. Unfortunately, there are many patients with glaucoma who are non-adherent. Non-adherence can be due to many things such as significant side effects on the ocular surface, lack of understanding of how to treat and why the treatment is important, and lack of effect of the treatment. Many of the challenges that patients with glaucoma experience can be reduced by ophthalmologists being aware of the challenges that come with the treatments. An important challenge is the use of preservatives in the eye drops. Preservatives cause unnecessary side effects and should at least be reduced or at best avoided. Another challenge is the use of generic eye drops that come with different packaging, different solvents, and not least different preservatives. For those patients who must undergo glaucoma surgery, there is a greater risk of an unsuccessful result if the conjunctiva is affected due to adverse effects from many years use of eye drops.

It is often difficult for patients with glaucoma to navigate the different treatment options. That is why information is so important. Also, patients with glaucoma are often in a difficult position. They may have lost their driving license, which can affect their sense of freedom and quality of life. All in all, it is important to see the patient as a whole person and to find the treatment with the least possible side effects,

which is also understandable for the patient. In addition, it is important that the text on the packaging is clear so that patients can read what they are putting in their eyes.

In summary, eye drops against glaucoma cause many adverse effects on the ocular surface and adnexae. These can lead to non-adherence and a poor outcome if the patients have to undergo surgery. Therefore, communication about the importance of the treatment is crucial for patients to continue the treatment despite the side effects. Although it is well known that preservatives cause side effects and should be minimized, it is important to know that the active substance and other factors such as phosphate content, pH and viscosity of the eye drops can have an adverse effect on the ocular surface.

In this report, the various challenges for glaucoma patients are discussed with a special focus on how to improve adherence and surgical outcome in patients, if the ocular adverse effects are minimized when the treatment is initiated in the individual patient.

## Disclosures

Miriam Kolko – Consultant/Advisor for Abbvie, Laboratoire Théa & Santen; Speaker Abbvie, Laboratoire Théa & Santen; Research support: Laboratoire Théa.

Gus Gazzard - Consultant/Advisor, Lecture Fees/Speakers Bureau: Alcon Laboratories/Ivantis, Allergan/Abvie, Glaukos Corporation, Reichert & Laboratoire Théa; Consultant/Advisor: Laser, Genentech/Roche, McKinsey Consulting, Ripple Therapeutics, Santen, Inc., Sight Sciences, Inc. and Vialase; Lecture Fees/Speakers Bureau: Bausch + Lomb, Haag-Streit Group, Lumenis, Inc., Lumibird/Quantel/Ellex, & Merck & Co., Inc.

Christophe Baudouin - consultant for Abbvie, Alcon, Horus Pharma, Oculis, Santen & Laboratoire Théa.

Sofie Beier - Nothing to declare.

Françoise Brignole-Baudouin - Nothing to declare.

Barbara Cvenkel - Consultant for Laboratoire Théa and Santen.

Fredrik Fineide - Nothing to declare.

Anton Hommer - Consultant for Nidek and Santen; Speaker for Laboratoire Théa, Santen, Nidek, Abbvie and Haag Streit.

Erik Jespersen - Nothing to declare.

Elisabeth M. Messmer - Speaker and/or consultant: Alcon Pharma GmbH, DMG, Dompé, Kala, Novartis, Pharm-Allergan GmbH, Santen GmbH, Shire, Sifi, Sun Pharmaceuticals, Laboratoire Théa, TRB-Chemedia, Ursapharm Arzneimittel GmbH & Visufarma

Rachna Murthy - Consultant for Allergan Aesthetics Abbvie, Lumenis, Essiri Labs & Purifeyes Hypochlorous.

Anne Hedengran - Nothing to declare.

Amy Gallant Sullivan - Equity in Essiri Labs.

Andrew J. Tatham - Consultant: Santen, Laboratoire Théa, Roche & Alcon; Speaker - Alcon, AbbVie, Santen, Laboratoire Théa & Sight Sciences; Research support: AbbVie.

Tor Paaske Utheim - Co-owner of The Norwegian dry eye clinic and the Clinic of eye health, Oslo, Norway, which delivers talks for and/or receives financial support from: ABIGO, Alcon, Allergan, AMWO, Bausch + Lomb, Bayer, European school for advanced studies in ophthalmology, InnZ Medical, Medilens Nordic, Medistim, Novartis, Santen, Specsavers, Shire Pharmaceuticals, Laboratoire Théa. He has served on the global scientific advisory board for Novartis and Alcon as well as the European advisory board for Shire Pharmaceuticals.

Marijke Vittrup - Nothing to declare.

David A. Sullivan - Equity in Essiri Labs & Lubris BioPharma.

## Declaration of competing interest

Financial disclosures are listed above.

## Acknowledgments

TFOS expresses its appreciation to Julie Karimi ([www.jaka.it](http://www.jaka.it)), Sabrina Zappia ([www.citynetonline.it](http://www.citynetonline.it)) and Jeremy Chung Bo Chiang (Sydney, Australia) for their outstanding assistance. TFOS also thanks the following industry partners who supported this TFOS Experts' Meeting with unrestricted donations: Santen, Bausch + Lomb, Dompé, Glaukos, URSAPHARM, Laboratoires Théa and VISUfarma.

## References

- [1] Tham YC, Li X, Wong TY, Quigley HA, Aung T, Cheng CY. Global prevalence of glaucoma and projections of glaucoma burden through 2040: a systematic review and meta-analysis. *Ophthalmology* 2014;121:2081–90.
- [2] Stapleton F, Alves M, Bunya VY, Jalbert I, Lekhanont K, Malet F, et al. TFOS DEWS II epidemiology report. *Ocul Surf* 2017;15:334–65.
- [3] Eberhardt M, Rammohan G. Blepharitis. StatPearls. Treasure Island (FL). StatPearls Publishing Copyright © 2022, StatPearls Publishing LLC.; 2022.
- [4] Gomes JAP, Azar DT, Baudouin C, Efron N, Hirayama M, Horwath-Winter J, et al. TFOS DEWS II iatrogenic report. *Ocul Surf* 2017;15:511–38.
- [5] Leung EW, Medeiros FA, Weinreb RN. Prevalence of ocular surface disease in glaucoma patients. *J Glaucoma* 2008;17:350–5.
- [6] Kolko M, Horwitz A, Thygesen J, Jeppesen J, Torp-Pedersen C. The prevalence and incidence of glaucoma in Denmark in a fifteen year period: a nationwide study. *PLoS One* 2015;10:e0132048.
- [7] Causes of blindness and vision impairment in 2020 and trends over 30 years, and prevalence of avoidable blindness in relation to VISION 2020: the Right to Sight: an analysis for the Global Burden of Disease Study. *Lancet Global Health* 2021;9:e144–60.
- [8] Ramulu PY, West SK, Munoz B, Jampel HD, Friedman DS. Driving cessation and driving limitation in glaucoma: the salisbury eye evaluation project. *Ophthalmology* 2009;116:1846–53.
- [9] Ramulu PY, Swenor BK, Jefferys JL, Rubin GS. Description and validation of a test to evaluate sustained silent reading. *Invest Ophthalmol Vis Sci* 2013;54:673–80.
- [10] Black AA, Wood JM, Lovie-Kitchin JE. Inferior field loss increases rate of falls in older adults with glaucoma. *Optom Vis Sci* 2011;88:1275–82.
- [11] Ramulu PY, Maul E, Hochberg C, Chan ES, Ferrucci L, Friedman DS. Real-world assessment of physical activity in glaucoma using an accelerometer. *Ophthalmology* 2012;119:1159–66.
- [12] Ramulu PY, Swenor BK, Jefferys JL, Friedman DS, Rubin GS. Difficulty with out-loud and silent reading in glaucoma. *Invest Ophthalmol Vis Sci* 2013;54:666–72.
- [13] Ramulu PY, van Landingham SW, Massof RW, Chan ES, Ferrucci L, Friedman DS. Fear of falling and visual field loss from glaucoma. *Ophthalmology* 2012;119:1352–8.
- [14] Kapetanakis VV, Chan MP, Foster PJ, Cook DG, Owen CG, Rudnicka AR. Global variations and time trends in the prevalence of primary open angle glaucoma (POAG): a systematic review and meta-analysis. *Br J Ophthalmol* 2016;100:86–93.
- [15] Kang JM, Tanna AP. Glaucoma. *Med Clin North Am* 2021;105:493–510.
- [16] Chan MPY, Broadway DC, Khawaja AP, Yip JLY, Garway-Heath DF, Burr JM, et al. Glaucoma and intraocular pressure in EPIC-Norfolk Eye Study: cross sectional study. *BMJ* 2017;358:j3889.
- [17] Traverso CE, Walt JG, Kelly SP, Hommer AH, Bron AM, Denis P, et al. Direct costs of glaucoma and severity of the disease: a multinational long term study of resource utilisation in Europe. *Br J Ophthalmol* 2005;89:1245–9.
- [18] Wang K, Gaitsch H, Poon H, Cox NJ, Rzhetsky A. Classification of common human diseases derived from shared genetic and environmental determinants. *Nat Genet* 2017;49:1319–25.
- [19] Owen CG, Carey IM, Shah S, de Wilde S, Wormald R, Whincup PH, et al. Hypotensive medication, statins, and the risk of glaucoma. *Invest Ophthalmol Vis Sci* 2010;51:3524–30.
- [20] Baudouin C, Kolko M, Melik-Parsadaniants S, Messmer EM. Inflammation in glaucoma: from the back to the front of the eye, and beyond. *Prog Retin Eye Res* 2021;83:100916.
- [21] Vohra R, Tsai JC, Kolko M. The role of inflammation in the pathogenesis of glaucoma. *Surv Ophthalmol* 2013;58:311–20.
- [22] Lopez Sanchez MI, Crowston JG, Mackey DA, Trounce IA. Emerging mitochondrial therapeutic targets in optic neuropathies. *Pharmacol Ther* 2016;165:132–52.
- [23] Petriti B, Williams PA, Lascaratos G, Chau KY, Garway-Heath DF. Neuroprotection in glaucoma: NAD(+)/NADH redox state as a potential biomarker and therapeutic target. *Cells* 2021;10.
- [24] Mitchell P, Hourihan F, Sandbach J, Wang JJ. The relationship between glaucoma and myopia: the blue mountains eye study. *Ophthalmology* 1999;106:2010–5.
- [25] Heijl A, Leske MC, Bengtsson B, Hyman L, Bengtsson B, Hussein M. Reduction of intraocular pressure and glaucoma progression: results from the Early Manifest Glaucoma Trial. *Arch Ophthalmol* 2002;120:1268–79.
- [26] Shestopalov VI, Spurlock M, Gramlich OW, Kuehn MH. Immune responses in the glaucomatous retina: regulation and dynamics. *Cells* 2021;10.
- [27] Cvenkel B, Kolko M. Current medical therapy and future trends in the management of glaucoma treatment. *J Ophthalmol* 2020;6138132. 2020.
- [28] Kalouda P, Keskin C, Anastasopoulos E, Topouzis F. Achievements and limits of current medical therapy of glaucoma. *Dev Ophthalmol* 2017;59:1–14.
- [29] Müllertz O, Hedengran A, Mouhammad ZA, Freiberg J, Nagymihály R, Jacobsen J, et al. Impact of benzalkonium chloride-preserved and preservative-free latanoprost eye drops on cultured human conjunctival goblet cells upon acute exposure and differences in physicochemical properties of the eye drops. *BMJ Open Ophthalmol* 2021;6:e000892.
- [30] Kolko M, Koch Jensen P. The physical properties of generic latanoprost ophthalmic solutions are not identical. *Acta Ophthalmol* 2017;95:370–3.
- [31] Queen JH, Feldman RM, Lee DA. Variation in number of doses, bottle volume, and calculated yearly cost of generic and branded latanoprost for glaucoma. *Am J Ophthalmol* 2016;163:70. 4.e1.
- [32] Golan S, Rosenfeld E, Shemesh G, Kurtz S. Original and generic latanoprost for the treatment of glaucoma and ocular hypertension: are they really the same? *Clin Exp Pharmacol Physiol* 2015;42:220–4.
- [33] Stein JD, Shekhawat N, Talwar N, Balkrishnan R. Impact of the introduction of generic latanoprost on glaucoma medication adherence. *Ophthalmology* 2015;122:738–47.
- [34] Egan P, Harris A, Siesky B, Abrams-Tobe L, Gerber AL, Park J, et al. Comparison of intraocular pressure in glaucoma subjects treated with Xalatan versus generic latanoprost. *Acta Ophthalmol* 2014;92:e415–6.
- [35] Steensberg AT, Müllertz OO, Virgili G, Azuara-Blanco A, Kolko M. Evaluation of generic versus original prostaglandin analogues in the treatment of glaucoma: a systematic review and meta-analysis. *Ophthalmol Glaucoma* 2020;3:51–9.
- [36] Fineide F, Lagali N, Adil MY, Arita R, Kolko M, Vehof J, et al. Topical glaucoma medications - clinical implications for the ocular surface. *Ocul Surf* 2022;26:19–49.
- [37] Dubrulle P, Labbé A, Brasnu E, Liang H, Hamard P, Meziani L, et al. Influence of treating ocular surface disease on intraocular pressure in glaucoma patients intolerant to their topical treatments: a report of 10 cases. *J Glaucoma* 2018;27:1105–11.
- [38] Stalmans I, Lemij H, Clarke J, Baudouin C. Signs and symptoms of ocular surface disease: the reasons for patient dissatisfaction with glaucoma treatments. *Clin Ophthalmol* 2020;14:3675–80.
- [39] Jaenen N, Baudouin C, Pouliquen P, Manni G, Figueiredo A, Zeyen T. Ocular symptoms and signs with preserved and preservative-free glaucoma medications. *Eur J Ophthalmol* 2007;17:341–9.
- [40] Erb C, Gast U, Schremmer D. German register for glaucoma patients with dry eye. I. Basic outcome with respect to dry eye. *Graefes Arch Clin Exp Ophthalmol* 2008;246:1593–601.
- [41] Fechtner RD, Godfrey DG, Budenz D, Stewart JA, Stewart WC, Jasek MC. Prevalence of ocular surface complaints in patients with glaucoma using topical intraocular pressure-lowering medications. *Cornea* 2010;29:618–21.
- [42] Pisella PJ, Pouliquen P, Baudouin C. Prevalence of ocular symptoms and signs with preserved and preservative free glaucoma medication. *Br J Ophthalmol* 2002;86:418–23.
- [43] Kuppens EV, van Best JA, Sterk CC, de Keizer RJ. Decreased basal tear turnover in patients with untreated primary open-angle glaucoma. *Am J Ophthalmol* 1995;120:41–6.
- [44] Neves Mendes CR, Hida RY, Kasahara N. Ocular surface changes in eyes with glaucoma filtering blebs. *Curr Eye Res* 2012;37:309–11.
- [45] Ji H, Zhu Y, Zhang Y, Li Z, Ge J, Zhuo Y. Dry eye disease in patients with functioning filtering blebs after trabeculectomy. *PLoS One* 2016;11:e0152696.
- [46] Blondeau P, Rousseau JA. Allergic reactions to brimonidine in patients treated for glaucoma. *Can J Ophthalmol* 2002 Feb;37(1):21–6. [https://doi.org/10.1016/s0008-4182\(02\)80094-1](https://doi.org/10.1016/s0008-4182(02)80094-1).
- [47] Yeh PH, Cheng YC, Shie SS, Lee YS, Shen SC, Chen HS, et al. Brimonidine related acute follicular conjunctivitis: Onset time and clinical presentations, a long-term follow-up. *Medicine (Baltimore)* 2021 Jul 23;100(29):e26724. <https://doi.org/10.1097/MD.00000000000026724>.
- [48] Williams GC, Orengo-Nania S, Gross RL. Incidence of brimonidine allergy in patients previously allergic to apraclonidine. *J Glaucoma* 2000 Jun;9(3):235–8. <https://doi.org/10.1097/00061198-200006000-00006>.
- [49] Espinola S, Mora D. [Type IV hypersensitivity to timolol]. *Rev Alerg Mex* 2020;67:293–6.
- [50] Ahlström MG, Skov L, Heegaard S, Zachariae C, Garvey LH, Johansen JD. Topical eye medications causing allergic contact dermatitis. *Contact Dermatitis* 2023;88:294–9.
- [51] Yuan X, Ma X, Yang L, Zhou Q, Li Y.  $\beta$ -blocker eye drops affect ocular surface through  $\beta$ 2 adrenoceptor of corneal limbal stem cells. *BMC Ophthalmol* 2021;21:419.
- [52] Hino K, Mori K, Sotozono C, Ikeda Y, Naruse S, Ishibashi T, et al. [A case of severe glaucoma with pseudophakic glaucoma successfully treated by filtration surgery using amniotic membrane]. *Nippon Ganka Gakkai Zasshi* 2006;110:312–7.
- [53] Patchinsky A, Petitpain N, Gillet P, Angioi-Duprez K, Schmutz JL, Bursztejn AC. Dermatological adverse effects of anti-glaucoma eye drops: a review. *J Eur Acad Dermatol Venereol* 2022;36:661–70.
- [54] Tong L, Hou AH, Wong TT. Altered expression level of inflammation-related genes and long-term changes in ocular surface after trabeculectomy, a prospective cohort study. *Ocul Surf* 2018;16:441–7.
- [55] Weinreb RN. Enhancement of scleral macromolecular permeability with prostaglandins. *Trans Am Ophthalmol Soc* 2001;99:319–43.
- [56] Yamada H, Yoneda M, Gosho M, Kato T, Zako M. Bimatoprost, latanoprost, and tafluprost induce differential expression of matrix metalloproteinases and tissue inhibitor of metalloproteinases. *BMC Ophthalmol* 2016;16:26.
- [57] Brasnu E, Brignole-Baudouin F, Riancho L, Guenoun JM, Warnet JM, Baudouin C. In vitro effects of preservative-free tafluprost and preserved latanoprost,

- travoprost, and bimatoprost in a conjunctival epithelial cell line. *Curr Eye Res* 2008;33:303–12.
- [58] Robciuc A, Witos J, Ruokonen SK, Rantamäki AH, Pisella PJ, Wiedmer SK, et al. Pure glaucoma drugs are toxic to immortalized human corneal epithelial cells, but they do not destabilize lipid membranes. *Cornea* 2017;36:1249–55.
- [59] Liu Y, Liu Y, Xu D, Li J. Latanoprost-induced cytokine and chemokine release from human Tenon's capsule fibroblasts: role of MAPK and NF- $\kappa$ B signaling pathways. *J Glaucoma* 2015;24:635–41.
- [60] Oda M, Takahashi N. Cell injury effect of isopropyl unoprostone, an antiglaucoma agent, on cultured human conjunctival cells. *J Ocul Pharmacol Therapeut* 1999; 15:489–96.
- [61] Trzeciacka A, Paterno JJ, Toropainen E, Koskela A, Podracka L, Korhonen E, et al. Long-term topical application of preservative-free prostaglandin analogues evokes macrophage infiltration in the ocular adnexa. *Eur J Pharmacol* 2016;788: 12–20.
- [62] Rouland JF, Traverso CE, Stalmans I, Fekih LE, Delval L, Renault D, et al. Efficacy and safety of preservative-free latanoprost eyedrops, compared with BAK-preserved latanoprost in patients with ocular hypertension or glaucoma. *Br J Ophthalmol* 2013;97:196–200.
- [63] Goldberg I, Gil Pina R, Lanzagorta-Aresti A, Schiffman RM, Liu C, Bejanian M. Bimatoprost 0.03%/timolol 0.5% preservative-free ophthalmic solution versus bimatoprost 0.03%/timolol 0.5% ophthalmic solution (Ganfort) for glaucoma or ocular hypertension: a 12-week randomised controlled trial. *Br J Ophthalmol* 2014;98:926–31.
- [64] Murugesan V, Dwivedi R, Saini M, Gupta V, Dada T, Vivekanandhan S. Tear neuromediators in eyes on chronic topical antiglaucoma therapy with and without BAK preservatives. *Br J Ophthalmol* 2021;105:141–8.
- [65] Baudouin C, Hamard P, Liang H, Creuzot-Garcher C, Bensoussan L, Brignole F. Conjunctival epithelial cell expression of interleukins and inflammatory markers in glaucoma patients treated over the long term. *Ophthalmology* 2004;111: 2186–92.
- [66] Rolle T, Spinetta R, Nuzzi R. Long term safety and tolerability of Tafluprost 0.0015% vs Timolol 0.1% preservative-free in ocular hypertensive and in primary open-angle glaucoma patients: a cross sectional study. *BMC Ophthalmol* 2017;17: 136.
- [67] Pisella PJ, Debasch C, Hamard P, Creuzot-Garcher C, Rat P, Brignole F, et al. Conjunctival proinflammatory and proapoptotic effects of latanoprost and preserved and unpreserved timolol: an ex vivo and in vitro study. *Invest Ophthalmol Vis Sci* 2004;45:1360–8.
- [68] Ciancaglini M, Carpineto P, Agnifili L, Nubile M, Fasanella V, Lanzini M, et al. An in vivo confocal microscopy and impression cytology analysis of preserved and unpreserved levobunolol-induced conjunctival changes. *Eur J Ophthalmol* 2008; 18:400–7.
- [69] Mastropasqua L, Agnifili L, Fasanella V, Curcio C, Ciabattoni C, Mastropasqua R, et al. Conjunctival goblet cells density and preservative-free tafluprost therapy for glaucoma: an in vivo confocal microscopy and impression cytology study. *Acta Ophthalmol* 2013;91:e397–405.
- [70] Fogagnolo P, Dipinto A, Vanzulli E, Maggiolo E, De Cilla S, Autelitano A, et al. A 1-year randomized study of the clinical and confocal effects of tafluprost and latanoprost in newly diagnosed glaucoma patients. *Adv Ther* 2015;32:356–69.
- [71] El Ameen A, Vandermeer G, Khanna RK, Pisella PJ. Objective ocular surface tolerance in patients with glaucoma treated with topical preserved or unpreserved prostaglandin analogues. *Eur J Ophthalmol* 2019;29:645–53.
- [72] Lopes NLV, Gracitelli CPB, Chalita MR, de Faria NVL. Ocular surface evaluation after the substitution of benzalkonium chloride preserved prostaglandin eye drops by a preservative-free prostaglandin analogue. *Med Hypothesis, Discov Innovation (MEHDI) Ophthalmol* 2019;8:52–6.
- [73] Milla E, Stirbu O, Rey A, Duch S, Buchaca O, Robles A, et al. Spanish multicenter tafluprost tolerability study. *Br J Ophthalmol* 2012;96:826–31.
- [74] Misiek-Hojlo M, Pomorska M, Mulak M, Rekas M, Wierzbowska J, Prost M, et al. The RELIEF study: tolerability and efficacy of preservative-free latanoprost in the treatment of glaucoma or ocular hypertension. *Eur J Ophthalmol* 2019;29:210–5.
- [75] Hommer A, Schmidl D, Kromus M, Bata AM, Fondi K, Werkmeister RM, et al. Effect of changing from preserved prostaglandins to preservative-free tafluprost in patients with glaucoma on tear film thickness. *Eur J Ophthalmol* 2018;28: 385–92.
- [76] Iester M, Telani S, Frezzotti P, Motolese I, Figus M, Fogagnolo P, et al. Ocular surface changes in glaucomatous patients treated with and without preservatives beta-blockers. *J Ocul Pharmacol Therapeut* 2014;30:476–81.
- [77] Rolle T, Curto D, Alovisi C, Franzoni M, Brogliatti B, Grignolo FM. Timogel® vs timolol 0.5% ophthalmic solution: efficacy, safety, and acceptance. *Eur J Ophthalmol* 2012;22:28–33.
- [78] Economou MA, Laukeland HK, Grabska-Liberek I, Rouland JF. Better tolerance of preservative-free latanoprost compared to preserved glaucoma eye drops: the 12-month real-life FREE study. *Clin Ophthalmol* 2018;12:2399–407.
- [79] Uusitalo H, Chen E, Pfeiffer N, Brignole-Baudouin F, Kaarniranta K, Leino M, et al. Switching from a preserved to a preservative-free prostaglandin preparation in topical glaucoma medication. *Acta Ophthalmol* 2010;88:329–36.
- [80] Zhang Y, Kam WR, Liu Y, Chen X, Sullivan DA. Influence of pilocarpine and timolol on human meibomian gland epithelial cells. *Cornea* 2017;36:719–24.
- [81] Han X, Liu Y, Kam WR, Sullivan DA. Effect of brimonidine, an  $\alpha$ 2 adrenergic agonist, on human meibomian gland epithelial cells. *Exp Eye Res* 2018;170:20–8.
- [82] Han X, Yang S, Kam WR, Sullivan DA, Liu Y. The carbonic anhydrase inhibitor dorzolamide stimulates the differentiation of human meibomian gland epithelial cells. *Curr Eye Res* 2020;45:1604–10.
- [83] Kam WR, Liu Y, Ding J, Sullivan DA. Do cyclosporine A, an IL-1 receptor antagonist, uridine triphosphate, rebamipide, and/or bimatoprost regulate human meibomian gland epithelial cells? *Invest Ophthalmol Vis Sci* 2016;57: 4287–94.
- [84] Ha JY, Sung MS, Park SW. Effects of preservative on the meibomian gland in glaucoma patients treated with prostaglandin analogues. *Chonnam Med J* 2019; 55:156–62.
- [85] Guo Y, Ha JY, Piao HL, Sung MS, Park SW. The protective effect of 3% diquafosol on meibomian gland morphology in glaucoma patients treated with prostaglandin analogs: a 12-month follow-up study. *BMC Ophthalmol* 2020;20:277.
- [86] Agnifili L, Fasanella V, Costagliola C, Ciabattoni C, Mastropasqua R, Frezzotti P, et al. In vivo confocal microscopy of meibomian glands in glaucoma. *Br J Ophthalmol* 2013;97:343–9.
- [87] Agnifili L, Mastropasqua R, Fasanella V, Brescia L, Scatena B, Oddone F, et al. Meibomian gland features and conjunctival goblet cell density in glaucomatous patients controlled with prostaglandin/timolol fixed combinations: a case control, cross-sectional study. *J Glaucoma* 2018;27:364–70.
- [88] Labetoulle M, Frau E, Le Jeune C. Systemic adverse effects of topical ocular treatments. *Presse Med* 2005;34:589–95.
- [89] Sira M, Verity DH, Malhotra R. Topical bimatoprost 0.03% and iatrogenic eyelid and orbital lipodystrophy. *Aesthetic Surg J* 2012;32:822–4.
- [90] Eftekhari K, Mifflin MD, Anderson RL. Prostaglandin-associated periorbital lipodystrophy in cosmetic eyelid surgery: a novel cause of facial asymmetry. *Aesthetic Surg J* 2016;36:Np119–N121.
- [91] Custer PL, Kent TL. Observations on prostaglandin orbitopathy. *Ophthalmic Plast Reconstr Surg* 2016;32:102–5.
- [92] Noma K, Kakizaki H. Bilateral upper eyelid retraction caused by topical bimatoprost therapy. *Ophthalmic Plast Reconstr Surg* 2012;28:e33–5.
- [93] De Gregorio A, Pedrotti E, Stevan G, Scala A, Lambiase A, Morselli S. Floppy eyelid syndrome and ectropion improvement after 1 month of 0.03% Bimatoprost topical therapy. *Am J Ophthalmol Case Rep* 2020;20:100938.
- [94] Peplinski LS, Albani Smith K. Deepening of lid sulcus from topical bimatoprost therapy. *Optom Vis Sci* 2004;81:574–7.
- [95] Inoue K, Shiokawa M, Wakakura M, Tomita G. Deepening of the upper eyelid sulcus caused by 5 types of prostaglandin analogs. *J Glaucoma* 2013;22:626–31.
- [96] Sakata R, Shirato S, Miyata K, Aihara M. Incidence of deepening of the upper eyelid sulcus on treatment with a tafluprost ophthalmic solution. *Jpn J Ophthalmol* 2014;58:212–7.
- [97] Kucukcilioglu M, Bayer A, Uysal Y, Altinsoy HI. Prostaglandin associated periorbitopathy in patients using bimatoprost, latanoprost and travoprost. *Clin Exp Ophthalmol* 2014;42:126–31.
- [98] Sakata R, Shirato S, Miyata K, Aihara M. Incidence of deepening of the upper eyelid sulcus in prostaglandin-associated periorbitopathy with a latanoprost ophthalmic solution. *Eye (Lond)*. 2014;28:1446–51.
- [99] Kim HW, Choi YJ, Lee KW, Lee MJ. Periorbital changes associated with prostaglandin analogs in Korean patients. *BMC Ophthalmol* 2017;17:126.
- [100] Shah M, Lee G, Lefebvre DR, Kronberg B, Loomis S, Brauner SC, et al. A cross-sectional survey of the association between bilateral topical prostaglandin analogue use and ocular adnexal features. *PLoS One* 2013;8:e61638.
- [101] Tan J, Berke S. Latanoprost-induced prostaglandin-associated periorbitopathy. *Optom Vis Sci* 2013;90:e245–7, discussion 1029.
- [102] Tappeiner C, Perren B, Iliev ME, Frueh BE, Goldblum D. [Orbital fat atrophy in glaucoma patients treated with topical bimatoprost—can bimatoprost cause enophthalmos?]. *Klin Monbl Augenheilkd* 2008;225:443–5.
- [103] Taketani Y, Yamagishi R, Fujishiro T, Igarashi M, Sakata R, Aihara M. Activation of the prostanoid FP receptor inhibits adipogenesis leading to deepening of the upper eyelid sulcus in prostaglandin-associated periorbitopathy. *Invest Ophthalmol Vis Sci* 2014;55:1269–76.
- [104] Higashiyama T, Minamikawa T, Kakinoki M, Sawada O, Ohji M. Decreased orbital fat and enophthalmos due to bimatoprost: quantitative analysis using magnetic resonance imaging. *PLoS One* 2019;14:e0214065.
- [105] Choi CJ, Tao W, Doddapaneni R, Acosta-Torres Z, Blessing NW, Lee BW, et al. The effect of prostaglandin analogue bimatoprost on thyroid-associated orbitopathy. *Invest Ophthalmol Vis Sci* 2018;59:5912–23.
- [106] Smith TJ. The putative role of prostaglandin endoperoxide H synthase-2 in the pathogenesis of thyroid-associated orbitopathy. *Exp Clin Endocrinol Diabetes* 1999;107(Suppl 5):S160–3.
- [107] Parrish RK, Palmberg P, Sheu WP. A comparison of latanoprost, bimatoprost, and travoprost in patients with elevated intraocular pressure: a 12-week, randomized, masked-evaluator multicenter study. *Am J Ophthalmol* 2003;135:688–703.
- [108] Shafi F, Madge SN. Skin graft hypertrichosis associated with prostaglandin analog in the treatment of glaucoma. *Ophthalmic Plast Reconstr Surg* 2014;30:e3–5.
- [109] Sharpe ED, Reynolds AC, Skuta GL, Jenkins JN, Stewart WC. The clinical impact and incidence of periocular pigmentation associated with either latanoprost or bimatoprost therapy. *Curr Eye Res* 2007;32:1037–43.
- [110] Inoue K, Shiokawa M, Higa R, Sugahara M, Soga T, Wakakura M, et al. Adverse periocular reactions to five types of prostaglandin analogs. *Eye (Lond)*. 2012;26: 1465–72.
- [111] Sun LL, Welch RT, Vu P. Lower eyelid melanoma during bimatoprost (Lumigan) therapy. *Clin Exp Ophthalmol* 2012;40:213–4.
- [112] Calladine D, Harrison RJ. Severe darkening of a facial skin graft from latanoprost. *Arch Ophthalmol* 2007;125:1427–8.
- [113] Dalgleish R. Idiopathic acquired lacrimal drainage obstruction. *Br J Ophthalmol* 1967;51:463–8.
- [114] Kashkouli MB, Beigi B, Murthy R, Astbury N. Acquired external punctal stenosis: etiology and associated findings. *Am J Ophthalmol* 2003;136:1079–84.



- [115] McNab AA. Lacrimal canalicular obstruction associated with topical ocular medication. *Aust N Z J Ophthalmol* 1998;26:219–23.
- [116] Kashkoui MB, Rezaee R, Nilforoushan N, Salimi S, Foroutan A, Naseripour M. Topical antiglaucoma medications and lacrimal drainage system obstruction. *Ophthalmic Plast Reconstr Surg* 2008;24:172–5.
- [117] Kashkoui MB, Pakdel F, Hashemi M, Ghaempanah MJ, Rezaee R, Kaghaz-Kanani R, et al. Comparing anatomical pattern of topical anti-glaucoma medications associated lacrimal obstruction with a control group. *Orbit* 2010;29:65–9.
- [118] Narioka J, Ohashi Y. Effects of beta-adrenergic antagonist on width of nasolacrimal drainage system lumen. *J Ocul Pharmacol Therapeut* 2007;23:467–75.
- [119] Baudouin C, Labbé A, Liang H, Pauly A, Brignole-Baudouin F. Preservatives in eyedrops: the good, the bad and the ugly. *Prog Retin Eye Res* 2010;29:312–34.
- [120] Goldstein MH, Silva FQ, Blender N, Tran T, Vantipalli S. Ocular benzalkonium chloride exposure: problems and solutions. *Eye (Lond)*. 2022;36:361–8.
- [121] Herreras JM, Pastor JC, Calonge M, Asensio VM. Ocular surface alteration after long-term treatment with an antiglaucomatous drug. *Ophthalmology* 1992;99:1082–8.
- [122] Clouzeau C, Godefroy D, Riancho L, Rostène W, Baudouin C, Brignole-Baudouin F. Hyperosmolarity potentiates toxic effects of benzalkonium chloride on conjunctival epithelial cells in vitro. *Mol Vis* 2012;18:851–63.
- [123] Magny R, Auzeil N, Olivier E, Kessal K, Regazzetti A, Dutot M, et al. Lipidomic analysis of human corneal epithelial cells exposed to ocular irritants highlights the role of phospholipid and sphingolipid metabolisms in detergent toxicity mechanisms. *Biochimie* 2020;178:148–57.
- [124] Chen X, Sullivan DA, Sullivan AG, Kam WR, Liu Y. Toxicity of cosmetic preservatives on human ocular surface and adnexal cells. *Exp Eye Res* 2018;170:188–97.
- [125] Sarkar J, Chaudhary S, Namavari A, Ozturk O, Chang JH, Yeo L, et al. Corneal neurotoxicity due to topical benzalkonium chloride. *Invest Ophthalmol Vis Sci* 2012;53:1792–802.
- [126] Martone G, Frezzotti P, Tosi GM, Traversi C, Mittica V, Malandrini A, et al. An in vivo confocal microscopy analysis of effects of topical antiglaucoma therapy with preservative on corneal innervation and morphology. *Am J Ophthalmol* 2009;147:725–735.e1.
- [127] Denoyer A, Godefroy D, Célérier I, Frugier J, Riancho L, Baudouin F, et al. CX3CL1 expression in the conjunctiva is involved in immune cell trafficking during toxic ocular surface inflammation. *Mucosal Immunol* 2012;5:702–11.
- [128] Lee HJ, Jun RM, Cho MS, Choi KR. Comparison of the ocular surface changes following the use of two different prostaglandin F<sub>2α</sub> analogues containing benzalkonium chloride or polyquad in rabbit eyes. *Cutan Ocul Toxicol* 2015;34:195–202.
- [129] Baudouin C, Liang H, Hamard P, Riancho L, Creuzot-Garcher C, Warnet JM, et al. The ocular surface of glaucoma patients treated over the long term expresses inflammatory markers related to both T-helper 1 and T-helper 2 pathways. *Ophthalmology* 2008;115:109–15.
- [130] Brignole-Baudouin F, Desbenoit N, Hamm G, Liang H, Both JP, Brunelle A, et al. A new safety concern for glaucoma treatment demonstrated by mass spectrometry imaging of benzalkonium chloride distribution in the eye, an experimental study in rabbits. *PLoS One* 2012;7:e50180.
- [131] Kestelyn PA, Kestelyn PG, De Bacquer D, Stevens AM. Switch from BAK-preserved to preservative-free latanoprost decreases anterior chamber flare in POAG patients. *Int Ophthalmol* 2019;39:105–9.
- [132] Charnock C. Are multidose over-the-counter artificial tears adequately preserved? *Cornea* 2006;25:432–7.
- [133] Abelson M, Fink K. How to handle BAK talk. *Rev Ophthalmol* 2002;9:52–4.
- [134] Steven DW, Alagband P, Lim KS. Preservatives in glaucoma medication. *Br J Ophthalmol* 2018;102:1497–503.
- [135] Rosin LM, Bell NP. Preservative toxicity in glaucoma medication: clinical evaluation of benzalkonium chloride-free 0.5% timolol eye drops. *Clin Ophthalmol* 2013;7:2131–5.
- [136] Committee for Medicinal Products for Human Use (CHMP). Guideline on excipients in the dossier for application for marketing authorisation of a medicinal product. [https://www.ema.europa.eu/en/documents/scientific-guide-line/guideline-excipients-dossier-application-marketing-authorisation-medicinal-product-revision-2\\_en.pdf](https://www.ema.europa.eu/en/documents/scientific-guide-line/guideline-excipients-dossier-application-marketing-authorisation-medicinal-product-revision-2_en.pdf). [Accessed 19 January 2023].
- [137] Weinreb RN, Araie M, Susanna R, et al., editors. 7th consensus meeting: medical treatment of glaucoma. Fort Lauderdale, FL: Kugler Publications; 2010.
- [138] European Medicines Agency (EMA). EMEA public statement on antimicrobial preservatives in ophthalmic preparations for human use. [https://www.ema.europa.eu/en/documents/public-statement/emea-public-statement-antimicrobial-preservatives-ophthalmic-preparations-human-use\\_en.pdf](https://www.ema.europa.eu/en/documents/public-statement/emea-public-statement-antimicrobial-preservatives-ophthalmic-preparations-human-use_en.pdf). [Accessed 20 January 2023].
- [139] Rasmussen CA, Kaufman PL. Exciting directions in glaucoma. *Can J Ophthalmol* 2014;49:534–43.
- [140] Kirwan JF, Lockwood AJ, Shah P, Macleod A, Broadway DC, King AJ, et al. Trabeculectomy in the 21st century: a multicenter analysis. *Ophthalmology* 2013;120:2532–9.
- [141] Gedde SJ, Schiffman JC, Feuer WJ, Herndon LW, Brandt JD, Budenz DL. Treatment outcomes in the Tube versus Trabeculectomy (TVT) study after five years of follow-up. *Am J Ophthalmol* 2012;153:789–803.e2.
- [142] Five-year follow-up of the fluorouracil filtering surgery study. The fluorouracil filtering surgery study group. *Am J Ophthalmol* 1996;121:349–66.
- [143] Lavin MJ, Wormald RP, Migdal CS, Hitchings RA. The influence of prior therapy on the success of trabeculectomy. *Arch Ophthalmol* 1990;108:1543–8.
- [144] Broadway DC, Grierson I, O'Brien C, Hitchings RA. Adverse effects of topical antiglaucoma medication. I. The conjunctival cell profile. *Arch Ophthalmol* 1994;112:1437–45.
- [145] Broadway DC, Grierson I, O'Brien C, Hitchings RA. Adverse effects of topical antiglaucoma medication. II. The outcome of filtration surgery. *Arch Ophthalmol* 1994;112:1446–54.
- [146] Broadway DC, Grierson I, Stürmer J, Hitchings RA. Reversal of topical antiglaucoma medication effects on the conjunctiva. *Arch Ophthalmol* 1996;114:262–7.
- [147] Khaw PT, Doyle JW, Sherwood MB, Grierson I, Schultz G, McGorray S. Prolonged localized tissue effects from 5-minute exposures to fluorouracil and mitomycin C. *Arch Ophthalmol* 1993;111:263–7.
- [148] Khaw PT, Sherwood MB, MacKay SL, Rossi MJ, Schultz G. Five-minute treatments with fluorouracil, floxuridine, and mitomycin have long-term effects on human Tenon's capsule fibroblasts. *Arch Ophthalmol* 1992;110:1150–4.
- [149] Md Noh SM, Sheikh Abdul Kadir SH, Bannur ZM, Froemming GA, Abdul Hamid Hasani N, Mohd Nawawi H, et al. Effects of ranibizumab on the extracellular matrix production by human Tenon's fibroblast. *Exp Eye Res* 2014;127:236–42.
- [150] Slabaugh M, Salim S. Use of anti-VEGF agents in glaucoma surgery. *J Ophthalmol* 2017;1645269. 2017.
- [151] Green E, Wilkins M, Bunce C, Wormald R. 5-Fluorouracil for glaucoma surgery. *Cochrane Database Syst Rev*; 2014Cd001132.
- [152] Lim R. The surgical management of glaucoma: a review. *Clin Exp Ophthalmol* 2022;50:213–31.
- [153] Muthusamy K, Tuft SJ. Iatrogenic limbal stem cell deficiency following drainage surgery for glaucoma. *Can J Ophthalmol* 2018;53:574–9.
- [154] Sauder G, Jonas JB. Limbal stem cell deficiency after subconjunctival mitomycin C injection for trabeculectomy. *Am J Ophthalmol* 2006;141:1129–30.
- [155] Sagara H, Sekiryu T, Noji H, Ogasawara M, Sugano Y, Horikiri H. Meibomian gland loss due to trabeculectomy. *Jpn J Ophthalmol* 2014;58:334–41.
- [156] European glaucoma society terminology and guidelines for glaucoma, 5th edition. *Br J Ophthalmol* 2021;105:1–169.
- [157] Medeiros FA. Biomarkers and surrogate endpoints: lessons learned from glaucoma. *Invest Ophthalmol Vis Sci* 2017;58. Bio20-bio6.
- [158] Ramulu P. Glaucoma and disability: which tasks are affected, and at what stage of disease? *Curr Opin Ophthalmol* 2009;20:92–8.
- [159] Beckers HJ, Schouten JS, Webers CA, van der Valk R, Hendrikse F. Side effects of commonly used glaucoma medications: comparison of tolerability, chance of discontinuation, and patient satisfaction. *Graefes Arch Clin Exp Ophthalmol* 2008;246:1485–90.
- [160] Parkkari M, Puroila P, Uusitalo H. Ocular surface disease signs and symptoms of glaucoma patients and their relation to glaucoma medication in Finland. *Eur J Ophthalmol* 2022;11206721221144339.
- [161] Qian L, Wei W. Identified risk factors for dry eye syndrome: a systematic review and meta-analysis. *PLoS One* 2022;17:e0271267.
- [162] World Health Organization. Adherence to long term therapies: evidence for action. 2003. Geneva, Switzerland.
- [163] Cho J, Niziol LM, Lee PP, Heisler M, Resnicow K, Musch DC, et al. Comparison of medication adherence assessment tools to identify glaucoma medication nonadherence. *Ophthalmol Glaucoma* 2022;5:137–45.
- [164] Rabiolo A, Barton K, McNaught AI. Patient-reported outcome measures should not be the primary outcome in glaucoma clinical trials of disease modification. *Br J Ophthalmol* 2023;107:3–5.
- [165] Fenwick EK, Man RE, Aung T, Ramulu P, Lamoureux EL. Beyond intraocular pressure: optimizing patient-reported outcomes in glaucoma. *Prog Retin Eye Res* 2020;76:100801.
- [166] Chalmers RL, Begley CG, Caffery B. Validation of the 5-Item Dry Eye Questionnaire (DEQ-5): discrimination across self-assessed severity and aqueous tear deficient dry eye diagnoses. *Contact Lens Anterior Eye* 2010;33:55–60.
- [167] Schiffman RM, Christianson MD, Jacobsen G, Hirsch JD, Reis BL. Reliability and validity of the ocular surface disease index. *Arch Ophthalmol* 2000;118:615–21.
- [168] Mathews PM, Ramulu PY, Friedman DS, Utine CA, Akpek EK. Evaluation of ocular surface disease in patients with glaucoma. *Ophthalmology* 2013;120:2241–8.
- [169] Thein AS, Hedengran A, Azuara-Blanco A, Arita R, Cvenkel B, Gazzard G, et al. Adverse effects and safety in glaucoma patients: agreement on clinical trial outcomes for reports on eye drops (ASGARD)-a Delphi consensus statement. *Am J Ophthalmol* 2022;241:190–7.
- [170] Baudouin C, Renard JP, Nordmann JP, Denis P, Lachkar Y, Sellem E, et al. Prevalence and risk factors for ocular surface disease among patients treated over the long term for glaucoma or ocular hypertension. *Eur J Ophthalmol* 2012;0.
- [171] Lemij HG, Hoevenaars JG, van der Windt C, Baudouin C. Patient satisfaction with glaucoma therapy: reality or myth? *Clin Ophthalmol* 2015;9:785–93.
- [172] Zhivov A, Kraak R, Bergter H, Kundt G, Beck R, Guthoff RF. Influence of benzalkonium chloride on langerhans cells in corneal epithelium and development of dry eye in healthy volunteers. *Curr Eye Res* 2010;35:762–9.
- [173] Goldberg I, Graham SL, Crowston JG, d'Mellow G. Clinical audit examining the impact of benzalkonium chloride-free anti-glaucoma medications on patients with symptoms of ocular surface disease. *Clin Exp Ophthalmol* 2015;43:214–20.
- [174] Kahook MY, Noecker R. Quantitative analysis of conjunctival goblet cells after chronic application of topical drops. *Adv Ther* 2008;25:743–51.
- [175] Sullivan DA, da Costa AX, Del Duca E, Doll T, Grupcheva CN, Lazreg S, et al. TFOS Lifestyle: impact of cosmetics on the ocular surface. *Ocul Surf* 2023. in press.
- [176] Alves M, Asbell P, Dogru M, Giannaccare G, Grau A, Gregory D, et al. TFOS Lifestyle Report: impact of environmental conditions on the ocular surface. *Ocul Surf* 2023. in press.

- [177] Abe RY, Diniz-Filho A, Costa VP, Gracitelli CP, Baig S, Medeiros FA. The impact of location of progressive visual field loss on longitudinal changes in quality of life of patients with glaucoma. *Ophthalmology* 2016;123:552–7.
- [178] Zhang X, Olson DJ, Le P, Lin FC, Fleischman D, Davis RM. The association between glaucoma, anxiety, and depression in a large population. *Am J Ophthalmol* 2017;183:37–41.
- [179] Kass MA, Heuer DK, Higginbotham EJ, Johnson CA, Keltner JL, Miller JP, et al. The Ocular Hypertension Treatment Study: a randomized trial determines that topical ocular hypotensive medication delays or prevents the onset of primary open-angle glaucoma. *Arch Ophthalmol* 2002;120:701–13. discussion 829–30.
- [180] Camp AS, Long CP, Galor A, Yamane M, Proudfoot JA, Weinreb RN. Dry eye symptom severity and visual field reliability metrics. *J Glaucoma* 2022;31:305–9.
- [181] Gazzard G, Konstantakopoulou E, Garway-Heath D, Garg A, Vickerstaff V, Hunter R, et al. Selective laser trabeculoplasty versus eye drops for first-line treatment of ocular hypertension and glaucoma (LiGHT): a multicentre randomised controlled trial. *Lancet* 2019;393:1505–16.
- [182] Garg A, Gazzard G. Treatment choices for newly diagnosed primary open angle and ocular hypertension patients. *Eye (Lond)*. 2020;34:60–71.
- [183] Rossi GC, Pasinetti GM, Scudeller L, Raimondi M, Lanteri S, Bianchi PE. Risk factors to develop ocular surface disease in treated glaucoma or ocular hypertension patients. *Eur J Ophthalmol* 2013;23:296–302.
- [184] Wolfram C, Stahlberg E, Pfeiffer N. Patient-reported nonadherence with glaucoma therapy. *J Ocul Pharmacol Therapeut* 2019;35:223–8.
- [185] Mocan MC, Uzunosmanoglu E, Kocabeyoglu S, Karakaya J, Irkec M. The association of chronic topical prostaglandin analog use with meibomian gland dysfunction. *J Glaucoma* 2016;25:770–4.
- [186] Ong ES, Felix ER, Levitt RC, Feuer WJ, Sarantopoulos CD, Galor A. Epidemiology of discordance between symptoms and signs of dry eye. *Br J Ophthalmol* 2018;102:674–9.
- [187] Medeiros FA, Sheybani A, Shah MM, Rivas M, Bai Z, Werts E, et al. Single administration of intracameral bimatoprost implant 10 µg in patients with open-angle glaucoma or ocular hypertension. *Ophthalmol Ther* 2022;11:1517–37.
- [188] Agnifili L, Fasanella V, Mastropasqua R, Frezzotti P, Curcio C, Brescia L, et al. In vivo goblet cell density as a potential indicator of glaucoma filtration surgery outcome. *Invest Ophthalmol Vis Sci* 2016;57:2928–35.
- [189] Romano D, De Ruvo V, Fogagnolo P, Farci R, Rossetti LM. Inter-eye comparison of the ocular surface of glaucoma patients receiving surgical and medical treatments. *J Clin Med* 2022;11.
- [190] Vaajanan A, Nättinen J, Aapola U, Gielen F, Uusitalo H. The effect of successful trabeculectomy on the ocular surface and tear proteomics—a prospective cohort study with 1-year follow-up. *Acta Ophthalmol* 2021;99:160–70.
- [191] Otarola F, Virgili G, Shah A, Hu K, Bunce C, Gazzard G. Ab interno trabecular bypass surgery with Schlemm’s canal microstent (Hydrus) for open angle glaucoma. *Cochrane Database Syst Rev* 2020;3:Cd012740.
- [192] Samuelson TW, Singh IP, Williamson BK, Falvey H, Lee WC, Odom D, et al. Quality of life in primary open-angle glaucoma and cataract: an analysis of VFQ-25 and OSDI from the iStent inject® pivotal trial. *Am J Ophthalmol* 2021;229:220–9.
- [193] Berman A. Reducing medication errors through naming, labeling, and packaging. *J Med Syst* 2004;28:9–29.
- [194] van der Waade K. Medical information design and its legislation. In: Black A, Luna P, Lund O, et al., editors. *Information design*. UK: Routledge; 2017.